

Supplementary materials

Developing a rat model of dilated cardiomyopathy with improved survival

Li-juan SHEN, Shu LU, Yong-hua ZHOU, Lan LI, Qing-min XING, Yong-liang XU

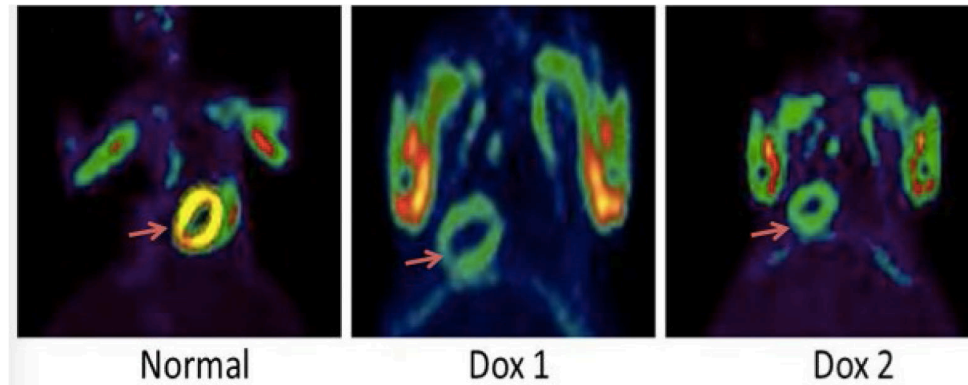


Fig. S1 Myocardial metabolism imaging by ^{18}F FDG-PET

Myocardial metabolism imaging reveals cardiac metabolic deficiencies with doxorubicin treatment. There was a significant decrease in the standard uptake values of the FDG uptake, indicating reduced myocardial viability