



Improved myocardial perfusion and cardiac function by controlled-release basic fibroblast growth factor using fibrin glue in a canine infarct model*

Shao-ping NIE^{†1}, Xiao WANG¹, Shi-bin QIAO¹, Qiu-tang ZENG², Ju-quan JIANG²,
 Xiao-qing LIU², Xiang-ming ZHU², Guo-xiang CAO², Chang-sheng MA¹

⁽¹⁾Department of Cardiology, Beijing Anzhen Hospital, Capital Medical University, Beijing 100029, China)

⁽²⁾Union Hospital of Tongji Medical College, Huazhong University of Science and Technology, Wuhan 430030, China)

[†]E-mail: spnie@126.com

Received Aug. 16, 2010; Revision accepted Oct. 28, 2010; Crosschecked Nov. 8, 2010

Abstract: Objective: Angiogenic therapy is emerging as a potential strategy for the treatment of ischemic heart disease but is limited by a relatively short half-life of growth factors. Fibrin glue (FG) provides a reservoir for controlled-release of growth factors. The aim of this study was to evaluate the effects of basic fibroblast growth factor (bFGF) incorporating FG on angiogenesis and cardiac performance in a canine infarct model. Methods: Acute myocardial infarction was induced by ligation of the left anterior descending coronary artery (LAD). Group I ($n=6$) underwent ligation of LAD alone. In Group II, transmural channels were created in the infarct area ($n=6$). In Group III, non-transmural channels were created to locate FG cylinders containing bFGF ($n=6$). Eight weeks after operation, myocardial perfusion was assessed by single photon emission computed tomography, cardiac function by echocardiography, and vascular development by immunohistochemical staining. Results: Total vascular density and the number of large vessels (internal diameter $\geq 50 \mu\text{m}$) were dramatically higher in Group III than in Groups I and II at eight weeks. Only the controlled-release group exhibited an improvement in regional myocardial perfusion associated with lower defect score. Animals in Group III presented improved cardiac regional systolic and diastolic functions as well as global systolic function in comparison with the other two groups. Conclusions: Enhanced and sustained angiogenic response can be achieved by controlled-release bFGF incorporating FG within transmural laser channels, thus enabling improvement in myocardial perfusion and cardiac function.

Key words: Angiogenesis, Basic fibroblast growth factor, Controlled release, Ischemic heart disease

doi:10.1631/jzus.B1000302

Document code: A

CLC number: R54

1 Introduction

Therapeutic angiogenesis has emerged as a promising strategy for the treatment of patients with end-stage coronary artery disease who are not suitable candidates for surgical or percutaneous revas-

cularization (Henry *et al.*, 2003; 2007; Kastrup *et al.*, 2005; Stewart *et al.*, 2009). Basic fibroblast growth factor (bFGF), a potent mitogen, has the ability to induce endothelial and smooth muscle cell proliferation in vitro and elicit in vivo angiogenesis that includes the migration and proliferation of endothelial cells, vascular tube formation, and linkage to the pre-existing vascular network (Beenken and Mohammadi, 2009). Considerable enthusiasm has arisen from numerous preclinical studies demonstrating improvements in perfusion, function, and vascularity utilizing

* Project supported by the National Natural Science Foundation of China (No. 81070166), and the Scientific Research Common Program of Beijing Municipal Commission of Education (No. KM201010 025020), China

© Zhejiang University and Springer-Verlag Berlin Heidelberg 2010

bFGF-related protein therapy in a variety of animal models (Harada *et al.*, 1994; Kawasuji *et al.*, 2000). However, the translation of this experience into clinical practice has been disappointing for a few recurring reasons (Laham *et al.*, 2000; Simons *et al.*, 2002). One of the proposed problems is insufficient delivery of growth factors due to a short half-life in the body (Post *et al.*, 2001).

Fibrin glue (FG), a natural component of the extracellular matrix, has been widely used as a tissue sealant in surgery (Currie *et al.*, 2001; Karacal *et al.*, 2007). Since fibrin sealant is lysed slowly, it can serve as a vehicle to slowly release various agents (Fasol *et al.*, 1994; Kang *et al.*, 1995). It is hypothesized that bFGF incorporating FG can be released at a steady rate and generate an effective concentration over a prolonged period of time, eliciting a controlled and sustained angiogenic response. The administration of FG containing bFGF directly into transmural laser channels may have a synergistic angiogenic effect (Heilmann *et al.*, 2003). In the present study, we used an FG carrier to evaluate whether the controlled-release bFGF in transmural channels would further stimulate neovascularization and hereby resume cardiac perfusion and function in a canine infarct model.

2 Materials and methods

2.1 Preparation of bFGF incorporating FG

Human recombinant bFGF was supplied by Shuanghe Pharmaceutical Co., Ltd., Beijing, China, and the FG kit was obtained from Shanghai Xinxing Blood Product Research Institute, China. The FG used in this study is a two-component system that remains liquid after mixing for several seconds before solidifying into a solid gel matrix. Briefly, lyophilized human fibrinogen was dissolved in sterile 0.9% (w/v) sodium chloride at final concentration of 40 mg/ml (Solution I). Lyophilized human thrombin was further diluted in 40 mmol/L calcium chloride to obtain final concentration of 500 U/ml (Solution II). For bFGF incorporating fibrin glue, 35 µg of bFGF was added to 0.5 ml of Solution II at a final concentration of 70 µg/ml (bFGF-thrombin, Solution III). The 0.5 ml of Solutions I and III were prepared for the following procedure.

2.2 Animal model and grouping

All animals received humane care in compliance with the “Principles of Laboratory Animal Care” formulated by the National Society for Medical Research of China and the “Guide for the Care and Use of Laboratory Animals” prepared by the National Academy of Sciences of China (National Institutes of Health Publication 85-23, revised 1985). A total of 18 adult male mongrel dogs weighing 15 to 20 kg (provided by Weitonglihua Experimental Animal Center, Beijing, China) were studied. They were fed a normal diet and housed individually under controlled environmental conditions (20–25 °C room temperature, 55%–65% relative humidity). The animals were anesthetized with intravenous administration of thiopental sodium (15 mg/kg) and then maintained with ketamine, incubated and mechanically ventilated (Newport NMI Wave E200). A small left thoracotomy through the 5th intercostal space was performed to expose the heart using a sterile technique. The left anterior descending coronary artery (LAD), distal to its first diagonal branch, was isolated and partially ligated with a 3.0 polypropylene suture for ischemic preconditioning for 20 min, with changes in pressure and electrocardiography (ECG) observed and lidocaine (1 mg/kg) injected intravenously when necessary. It was then completely ligated to establish an acute myocardial infarction model.

Thirty minutes after ligation, the dogs were randomized into three groups. Group I ($n=6$) served as blank control and had acute myocardial infarction alone. In Group II ($n=6$), transmural channels were made in the infarct area at the density of 1 channel/cm²; an average of 11 (range 10–12) channels were made in each heart. Potassium-titanyl-phosphate (KTP) double-frequency Nd:YAG (neodymium-doped yttrium aluminium garnet; Nd:Y₃Al₅O₁₂) laser (Laser Technology and Engineering Research Institute, Huazhong University of Science and Technology, Wuhan, China) was used. In Group III ($n=6$), non-transmural channels (10–12 channels per heart) were created in the infarct territory. A total of 0.5 ml of Solutions I and III were delivered through a double pump applicator, which holds the two components in separate syringes and provides simultaneous mixing and delivery. Notably, previous studies showed no significant angiogenic response in animals treated

with FG, suggesting that the angiogenic effects result entirely from the component contained in FG (Fasol *et al.*, 1994). After hemodynamic stability the pericardium and chest were closed, and the dogs were allowed to recover.

2.3 Myocardial perfusion imaging

Single photon emission computed tomography (SPECT) imaging with technetium-99m methoxyisobutylisonitrile (^{99m}Tc -MIBI) was conducted eight weeks after the surgery. Dogs were anesthetized with intravenous 3% (w/v) sodium pentobarbital (20–30 mg/kg) and were placed in the dorsal position in an SPECT scanner (Millennium VG, GE, Wisconsin, USA). SPECT images were acquired at 15 min after intravenous injection of ^{99m}Tc -MIBI [(244.2±37.0) MBq]. Briefly, projection data were acquired over 180° (right anterior oblique 45° to left posterior oblique 45°) using a 64×64 matrix in a 20% energy window (centered on the 140-keV X-ray photopeak), 30 s per 6° frame (totally 30 frames). All SPECT images were batch-reconstructed using standard filtered back-projection (order 4, cutoff 0.28×Nyquist frequency) without attenuation or scatter correction.

For each dog, the myocardial perfusion SPECT images were visually scored using a Cedars-Sinai 20-segment (CS-20) model (Fig. 1) and a 0–4 scale (0=normal uptake, 1=mildly reduced uptake, 2=moderately reduced uptake, 3=severely reduced uptake, and 4=no uptake), as previously described (Germano *et al.*, 2000). Two independent observers, who were blinded for related information, interpreted the images, and each segment was scored by consensus. The defect score was calculated as the sum of the perfusion defect. For each animal, a summed defect score in CS-20 and LAD territory (1, 2, 3, 7, 8,

9, 13, 14, 19, 20) and the number of segments (defect score >1) in CS-20 were calculated (Fig. 1).

2.4 Echocardiographic assessment of cardiac function

Left ventricular (LV) function was evaluated by transthoracic echocardiography using a Sequoia 256 system (ACUSON, California, USA) with a 3.0–5.5 MHz transducer. The following parameters were derived from the M-mode tracing: thickness of interventricular septum (IVS) and left ventricular anterior wall (LVAW) during systole and diastole to analyze regional wall thickening (ΔT), and motion amplitude (MA) and fractional shortening (FS) of LVAW. The variables measured on two-dimensional (2D) echocardiography were the left ventricular end-systolic dimension (LVESD) and the left ventricular end-diastolic dimension (LVEDD). LV ejection fraction (EF), stroke volume (SV), cardiac output (CO), and fractional area contraction (FAC) were calculated using the Simpson biplane method. Regional wall movement score index (WMSI) was calculated according to the guidelines of the American Society of Echocardiography (Bourdillon *et al.*, 1989). Based on a standard 16-segment model, wall motion was graded as follows: 1=normal; 2=hypokinetic (reduced systolic wall thickening); 3=akinetic (absent systolic wall thickening); or 4=dyskinetic (outward systolic wall motion). The systolic peak velocity (s) and the early-to-late diastolic peak velocity ratio (e/a) of the mitral valve (MV) and LVAW were determined by pulsed Doppler and pulsed Doppler tissue imaging (DTI). Echocardiograms were interpreted in a blinded manner by a cardiologist with expertise in echocardiography.

2.5 Histological study

After the SPECT and echocardiograph were performed, the dogs were euthanized and the hearts were excised. For dogs in Groups II and III, three infarct portions were cut off and fixed in 10% (v/v) buffered formalin. The transmural sections (3- μm) of the LV were embedded in paraffin stained with hematoxylin-eosin (H&E). Blood vessels were highlighted by staining endothelial cells for factor VIII-related antigen (Santa Cruz, California, USA) by applying the streptavidin-biotin peroxidase complex (SABC) method. Angiogenesis was assessed by

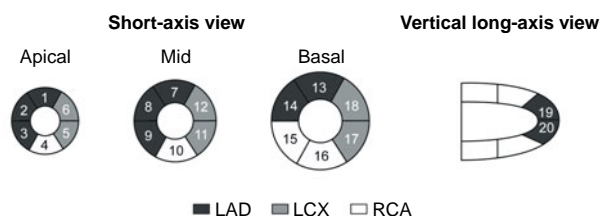


Fig. 1 Cedars-Sinai 20-segment model used for semi-quantitative visual scoring of perfusion (Germano *et al.*, 2000)

LAD: left anterior descending coronary artery; LCX: left circumflex coronary artery; RCA: right coronary artery

counting the number of microvessels, including capillaries (diameter $<20 \mu\text{m}$) and arterioles (diameter $\geq 20 \mu\text{m}$ and $<100 \mu\text{m}$ with tunica media), which were defined as round or elliptical structures with a clearly-defined lumen lined by cells staining positively to factor VIII. Three randomly selected high power fields (hpf) from each portion ($400\times$) were examined by two pathologists who were blinded to the grouping. The average number of the vessels in one portion was used for the assessment of vascular density. The same fields were selected to calculate microvessels with diameter $\geq 50 \mu\text{m}$ using an HPIAS-2000 image analysis system (Qianping Company of Imaging Technology of Tongji Medical College, Wuhan, China). Finally, the area of positive expression and average absorbance of factor VIII were analyzed at $200\times$ field with the HPIAS-2000 image analysis system. Three fields were randomly selected from each portion for quantitative analysis.

2.6 Statistical analysis

SPSS 15.0 (SPSS Science, Chicago, IL, USA) for Windows was used for statistical analysis and all data were presented as mean \pm standard deviation (SD). One-way analysis of variance (ANOVA) was used followed by Student-Newman-Keuls test for multiple comparisons. Values of $P<0.05$ were considered significant.

3 Results

Two (one in Group I; one in Group II) of 18 animals died on 22 and 34 d after surgery, respectively. There were no deaths related to transmural laser penetration and/or administration of bFGF incorporating FG. All other animals survived until euthanasia without postoperative complications and were used in the analysis (Group I, $n=5$; Group II, $n=5$; Group III, $n=6$).

3.1 Myocardial perfusion

SPECT images were divided into three different axes: short-axis images, vertical-axis images, and horizontal-axis images (Fig. 2a). Eight weeks after surgery, the control group showed a characteristic reduced perfusion corresponding to the occluded distal LAD: radioactivity of LVAW displayed degraded distribution. There was no apparent improvement of

perfusion in Group II. Images of Group III typically demonstrated improved myocardial blood perfusion in three axes.

There were no significant differences in the baseline defect score among the three groups ($P>0.05$). Regional defect scores were different after eight weeks. Group III demonstrated significantly lower total regional defect score in CS-20 and LAD territory compared with Groups I ($P<0.05$) and II ($P<0.05$) (Fig. 2b). In addition, there were less segments with a defect score >1 in Group III than in Groups I ($P<0.05$) and II ($P<0.05$) (Fig. 2c).

3.2 Cardiac function

Echocardiographic assessment of cardiac function demonstrated significant benefits in the controlled-release group vs. Groups I and II (Table 1). Eight weeks after the operation, the thickness of IVS during systole was significantly greater in Group III than in Groups I and II ($P<0.05$). ΔT was higher in Group III compared to Group I ($P<0.05$). Similarly, a much greater thickness of LVAW during diastole and systole was seen in the controlled-release group ($P<0.05$ in comparison with Groups I and II). Moreover, Group III exhibited enhanced MA and higher FS than the other two groups. All of the above data showed no significant difference between Groups I and II. Although no significant differences were found in LVEDD ($P=0.997$) and LVESD ($P=0.127$) among groups, EF, SV, CO, FAC, and WMSI as indexes of global systolic function revealed marked improvement in Group III. Compared to Groups I and II, SV and CO were higher and WMSI was lower in Group III ($P<0.05$). Importantly, DTI showed that in the sustained-release group, the e/a of LVAW was higher than that in Groups I and II ($P<0.05$). However, no significant differences were seen in e/a of MV in the three groups ($P=0.301$).

3.3 Vascular density

Blood vessels were highlighted by immunostaining for factor VIII (Fig. 3a). The endothelial cell dyed brown, single or clustered, was counted as one vessel. Total vascular density was dramatically higher in Group III [$n=18$, (44.00 ± 8.01) vessels/hpf] compared to Group I [$n=15$, (11.47 ± 3.89) vessels/hpf, $P<0.05$] and Group II [$n=15$, (34.27 ± 8.51) vessels/hpf, $P<0.05$] (Fig. 3b). A pathological image analysis

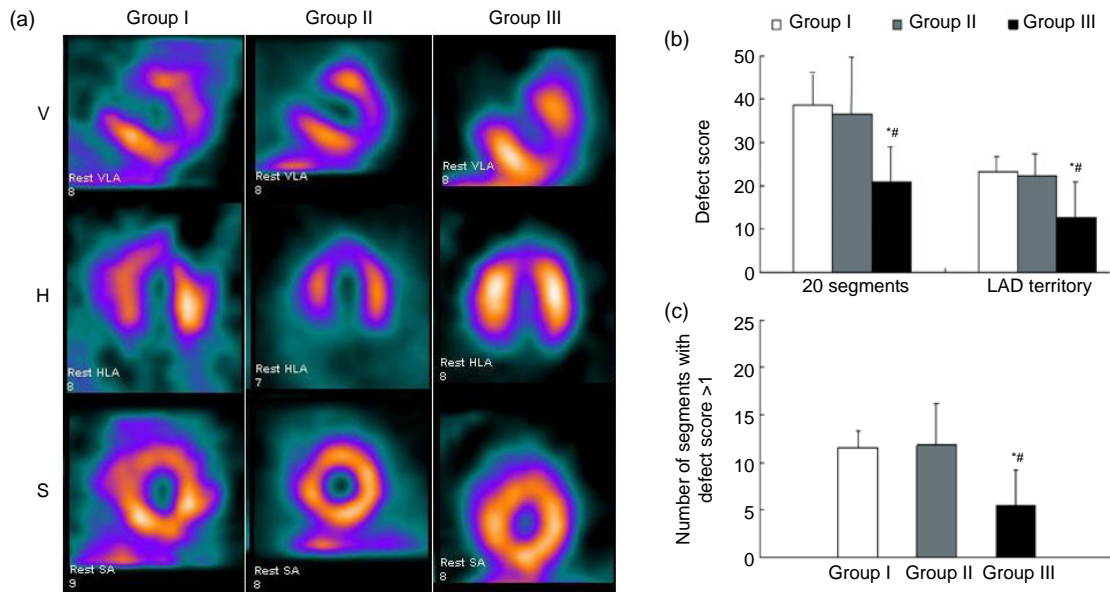


Fig. 2 Myocardial perfusion analysis

(a) Representative SPECT images of myocardial perfusion in three different groups. Group I demonstrated persistence of the ligation-induced LVAV perfusion defect. Group II exhibited slight improvement of blood perfusion. Group III exhibited large improvement of blood perfusion (V: vertical long axis; H: horizontal long axis; S: short axis); (b) Defect scores in 20 segments and LAD territory; (c) The number of segments with defect score >1. Values are expressed as mean±SD. * $P < 0.05$ vs. Group I; # $P < 0.05$ vs. Group II

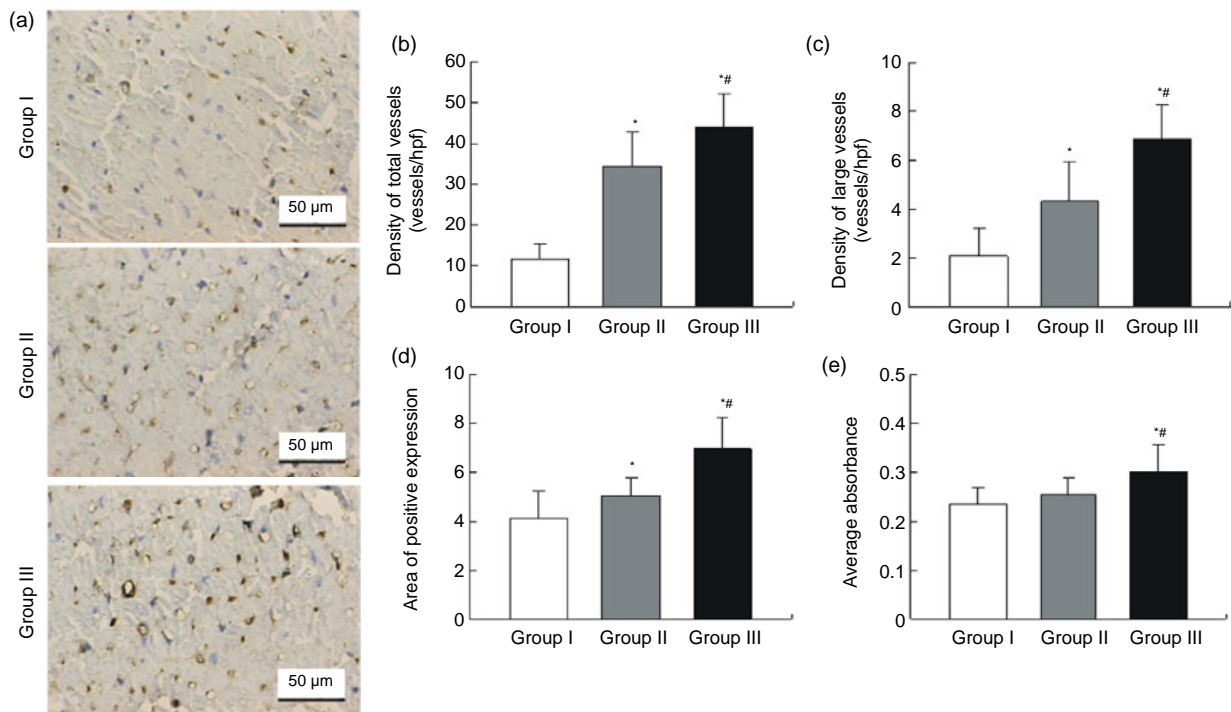


Fig. 3 Immunohistochemical staining and quantitative analysis eight weeks after surgery

(a) Representative images of myocardial sections depicting factor VIII-related antigen (brown). The microvessels are more numerous and larger in Group III than in Groups I and II; (b) The density of total vessels per high power field (hpf) in the infarct area; (c) The density of large vessels (internal diameter $\geq 50 \mu\text{m}$) per hpf in the infarct area; (d) The area of positive expression in the three groups; (e) The average absorbance among three groups. * $P < 0.05$ vs. Group I; # $P < 0.05$ vs. Group II

Table 1 Echocardiographic evaluation of cardiac regional and global functions

Parameter	Group I (n=5)	Group II (n=5)	Group III (n=6)	P value
IVS (M-mode)				
Thickness at diastole (cm)	0.37±0.05	0.39±0.05	0.47±0.10	0.078
Thickness at systole (cm)	0.52±0.07	0.58±0.06	0.75±0.19 ^{*#}	0.028
ΔT (%)	41.88±3.14	49.10±5.53	56.93±7.76 [*]	0.005
LVAW (M-mode)				
Thickness at diastole (cm)	0.36±0.04	0.38±0.07	0.51±0.09 ^{*#}	0.009
Thickness at systole (cm)	0.51±0.08	0.56±0.07	0.81±0.16 ^{*#}	0.002
ΔT (%)	40.99±6.04	51.08±11.9	57.70±10.09	0.053
MA (cm/s)	0.26±0.08	0.39±0.05	0.58±0.17 ^{*#}	0.002
FS (%)	23.84±4.54	33.42±5.49	46.54±10.42 ^{*#}	0.001
LVEDD (cm)	3.27±0.07	3.26±0.12	3.26±0.10	0.997
LVESD (cm)	2.25±0.09	2.21±0.06	2.13±0.12	0.127
EF (%)	47.60±7.54	55.18±1.96 [*]	60.68±4.76 [*]	0.007
SV (ml)	11.98±1.71	13.12±0.64	16.16±1.65 ^{*#}	0.002
CO (L/min)	1.48±0.14	1.59±0.10	1.86±0.11 ^{*#}	0.001
FAC (%)	32.12±4.29	37.38±4.83	43.76±8.85 [*]	0.040
WMSI	22.20±1.79	20.60±0.55 [*]	17.00±0.71 ^{*#}	<0.001
LVAW (DTI)				
s (cm/s)	0.86±0.14	1.18±0.24 [*]	1.36±0.24 [*]	0.010
e (cm/s)	0.74±0.15	1.04±0.25	0.96±0.20	0.095
a (cm/s)	0.83±0.19	0.91±0.11	0.60±0.11 ^{*#}	0.016
e/a	0.90±0.13	1.17±0.35	1.58±0.26 ^{*#}	0.006
MA (cm/s)	0.22±0.03	0.38±0.05 [*]	0.54±0.09 ^{*#}	<0.001
MV (DTI)				
e (cm/s)	0.76±0.16	0.70±0.14	0.72±0.14	0.809
a (cm/s)	0.67±0.12	0.58±0.13	0.47±0.06 [*]	0.034
e/a	1.20±0.44	1.26±0.37	1.58±0.38	0.301
HR (bpm)	122±5	121±4	118±5	0.463

Values are expressed as mean±SD. * $P < 0.05$ vs. Group I, # $P < 0.05$ vs. Group II. IVS: interventricular septum; ΔT: regional thickening; LVAW: left ventricular anterior wall; MA: motion amplitude; FS: fractional shortening; LVEDD: left ventricular end-diastolic dimension; LVESD: left ventricular end-systolic dimension; EF: ejection fraction; SV: stroke volume; CO: cardiac output; FAC: fractional area contraction; WMSI: regional wall movement score index; DTI: Doppler tissue imaging; s: systolic peak velocity; e: early diastolic peak velocity; a: late diastolic peak velocity; e/a: early-to-late diastolic peak velocity ratio; MV: mitral valve; HR: heart rate; bpm: beat per minute

system revealed that the density of large vessels, whose internal diameter (measured in the shortest direction) was at least 50 μm in the infarct area, was also higher in the controlled-release group [(6.89±1.41) vessels/hpf] than both Groups I [(2.07±1.16) vessels/hpf, $P < 0.05$] and II [(4.33±1.63) vessels/hpf, $P < 0.05$] (Fig. 3c). Quantitative analysis showed that the area of positive expression as well as average absorbance of factor VIII was greatly higher in Group III (Figs. 3d and 3e).

4 Discussion

The present study demonstrates that the administration of bFGF incorporating FG directly into

transmyocardial laser channels within an infarcted myocardium, results in greatly increased microvessels and significant improvement in regional myocardial perfusion. Importantly, this improvement is associated with enhanced cardiac regional and global function. Hence, these data indicate that controlled-release bFGF promote more efficient neovascularization.

The mechanical-stimulation and pharmacologic-stimulation of additional angiogenesis, in response to myocardial ischemia, have been tried for the treatment of patients with otherwise intractable angina pectoris. Despite favorable results with angiogenic growth factors such as bFGF, the optimal delivery of angiogenic growth factors remains problematic. Systemic or intracoronary delivery, while preferable owing to ease of use and clinical applicability, does

not achieve adequate concentrations in the myocardium to maximize efficacy (Laham *et al.*, 1999). Furthermore, such delivery methods for therapeutic angiogenesis have been incriminated in the proatherogenic effects, which may lead to plaque expansion or instability (Kornowski *et al.*, 2000a). Delivery of bFGF via direct myocardial injection can assist in the avoidance of high levels of circulating angiogenic activity but is confined to single administration and angioma. Recently, FG has been examined as a drug or growth-factor delivery vehicle, acting as an important material for tissue engineering. Particularly, fibrin plays an active role through specific receptor-mediated interactions with cells of the blood and vessel walls. These result in fibrin-specific responses of endothelial cells including adhesion and spreading, migration, and angiogenesis, which may be interrelated with the potent stimulation of the same responses by bFGF (Sahni *et al.*, 2006). This concept is supported by *in vitro* studies demonstrating that fibrin clots are an excellent matrix for bFGF-stimulated angiogenesis (DeBlois *et al.*, 1994; Brown *et al.*, 1996). The bFGF binds specifically and with high affinity to fibrinogen prior to the polymerization of the fibrin (Sahni *et al.*, 1998). The rate of bFGF release from FG can be controlled according to concentrations of fibrinogen and thrombin (Jeon *et al.*, 2005). Chawla *et al.* (1999) employed an angiogenic strategy that utilizes enhanced vascular endothelial growth factor (VEGF) in an FG in two patients with critical limb ischemia. The results angiographically demonstrated the growth of new blood vessels after administration of the VEGF and FG composite. The FG aids in the slow release of the growth factor and thus prolongs its availability, sustaining angiogenesis. On the basis of the above findings, we speculated that the controlled-release bFGF using FG might induce an enhanced angiogenic response and thus promote cardiac perfusion and function.

Sprouting angiogenesis is the best-understood mechanism of new blood vessel growth and involves the formation of new capillaries in response to ischemia or other stimuli. Arteriogenesis involves the widening of existing arteries and formation of collateral vessels and is capable of restoring a large volume of blood flow to a distal ischemic tissue (Phelps and Garcia, 2009). In a previous study, Yamamoto *et al.* (2000) injected bFGF into transmyo-

cardial channels in a pig model of chronic myocardial ischemia. The results showed that bFGF increased total vascular density by almost 40% over that observed in the control group. However, the number of large vessels (internal diameter $\geq 50 \mu\text{m}$) was doubled by the addition of bFGF. These data suggested that bFGF further enhances angiogenesis in ischemic myocardium mainly by increasing the size (collateral remodeling) but not the total number of vessels (Yamamoto *et al.*, 2000). In contrast, our histological investigation showed that total vascular density in the controlled-release group increased 28% over that in Group II, and this was associated with a 59% increase in the number of large vessels (internal diameter $\geq 50 \mu\text{m}$). This indicates that, except for angiogenesis, FG containing bFGF may induce arteriogenesis. Intramyocardial controlled-release bFGF seems to be more effective in producing a apparent and stable vasculature.

Previous clinical trial using percutaneous direct myocardial revascularization in patients with chronic refractory myocardial ischemia showed no significant improvement from nuclear perfusion imaging (Kornowski *et al.*, 2000b). Another animal study found improvements in myocardial perfusion and regional and global contractile reserve six months after transmyocardial laser revascularization (TMR) in a porcine model of hibernating myocardium (Hughes *et al.*, 1999). Our quantitative analysis using SPECT demonstrated a significantly increased perfusion in all segments as well as LAD territory eight weeks after the operation, compared with reversed changes happened in the control group. Notably, whereas the number of microvessels increased in both Groups II and III, better perfusion was rendered only by Group III. As mentioned above, slow-release bFGF further stimulated arteriogenesis, which has the ability to increase the lumen by growth. On the other hand, in addition to its mitogenic activity, bFGF has the ability to protect the myocardium acutely from tissue loss and dysfunction (House *et al.*, 2003; Jiang *et al.*, 2004). Accordingly, controlled-release bFGF enabled itself to work over a long period *in situ*, which induced rich angiogenesis and good collateral formation, while increasing regional blood flow around bFGF-injected sites.

It is expected that enhanced angiogenesis and improved perfusion will preserve LV function, because

LV functional loss may be attributable to insufficient blood flow that accompanies significant ischemic injury. In the present study, Group III exhibited significantly increased regional wall thickening and MA, which may be the result of improved local perfusion of hibernating myocardium adjacent to the infarct zone. However, no evident improvements were seen in Group II. This indicates LV regional systolic function benefits more from sustained-release bFGF in the transmural laser channels. Choi *et al.* (2006) recently demonstrated that intramyocardial injection of pCK-VEGF165 improved wall thickening and wall motion, but no benefit of EF was seen. Despite inconspicuous changes in LVEDD and LVESD, eight weeks after bFGF administration in our study, cardiac global systolic function (as represented by EF, SV, CO, and WMSI) was strikingly improved. These results suggest that bFGF-impregnated FG had no significant effects on ventricular remodeling process, although myocardial perfusion and cardiac function were markedly improved. The negative results may be ascribed to a short follow-up period (Sutton and Sharpe, 2000).

There are few experimental and clinical trials regarding the effect of controlled-release bFGF on cardiac diastolic function. Furthermore, Iwakura *et al.* (2003) presented that Tau, the time constant of isovolumic-relaxation, as an index of global diastolic function, was significantly smaller after intramyocardial injection of bFGF-impregnated gelatin hydrogel. We herein evaluated cardiac diastolic function in detail using a DTI technique. The e/a of LVAW was markedly higher in Group III, but no significant differences were found with respect to e/a of MV, suggesting controlled-release bFGF enables the improvement of cardiac regional diastolic function. The global diastolic function was not restored, probably owing to incomplete improvement of myocardial ischemia after angiogenic therapy.

Several modalities of controlled-release system with various vehicles have been evaluated. Lopez *et al.* (1997) reported that the sustained release of bFGF with alginate microsphere results in a significant improvement in myocardial function in the presence of chronic myocardial ischemia. Since the alginate is a poorly biodegradable polysaccharide, it may be difficult to control the carrier degradation. In contrast, an accumulating body of evidence exists that slow-

release bFGF incorporated into a biodegradable gelatin hydrogel can promote growth of microvessels and improve LV function (Iwakura *et al.*, 2003; Shao *et al.*, 2006). In consistence with these researchers, our study group investigated the effects of a new controlled-release system utilizing FG containing bFGF on cardiac performance, which achieved encouraging results.

However, there are still some limitations for our study. First, the acute myocardial infarction model in the present study does not represent chronic myocardial ischemia that is more often seen in the clinical setting. However, this method can be applied as an additional therapeutic regimen to those patients who are not suitable for percutaneous or surgical revascularization after acute infarction. Second, this study did not evaluate the use of FG without bFGF as an additional control group, although previous studies have demonstrated no extra angiogenic response with FG alone (Fasol *et al.*, 1994). Third, we used just one administration regimen of bFGF. Therefore, further studies are warranted to clarify the dose-effect relationship and to subsequently obtain the optimal efficacy.

5 Conclusions

The present study showed that controlled-release bFGF incorporating FG in transmural channels could augment angiogenesis, improve myocardial perfusion, and preserve cardiac regional and global function. The synergistic approach may maximize the benefit of therapeutic angiogenesis and provide a novel strategy for patients with ischemic heart disease.

References


- Beenken, A., Mohammadi, M., 2009. The FGF family: biology, pathophysiology and therapy. *Nat. Rev. Drug Discov.*, **8**(3):235-253. [doi:10.1038/nrd2792]
- Bourdillon, P.D., Broderick, T.M., Sawada, S.G., Armstrong, W.F., Ryan, T., Dillon, J.C., Fineberg, N.S., Feigenbaum, H., 1989. Regional wall motion index for infarct and noninfarct regions after reperfusion in acute myocardial infarction: comparison with global wall motion index. *J. Am. Soc. Echocardiogr.*, **2**(6):398-407.
- Brown, K.J., Maynes, S.F., Bezos, A., Maguire, D.J., Ford, M.D., Parish, C.R., 1996. A novel in vitro assay for human angiogenesis. *Lab. Invest.*, **75**(4):539-555.

- Chawla, P.S., Keelan, M.H., Kipshidze, N., 1999. Angiogenesis for the treatment of vascular diseases. *Int. Angiol.*, **18**(3):185-192.
- Choi, J.S., Kim, K.B., Han, W., Kim, D.S., Park, J.S., Lee, J.J., Lee, D.S., 2006. Efficacy of therapeutic angiogenesis by intramyocardial injection of pCK-VEGF165 in pigs. *Ann. Thorac. Surg.*, **82**(2):679-686. [doi:10.1016/j.athoracsur.2006.03.028]
- Currie, L.J., Sharpe, J.R., Martin, R., 2001. The use of fibrin glue in skin grafts and tissue-engineered skin replacements: a review. *Plast. Reconstr. Surg.*, **108**(6):1713-1726. [doi:10.1097/00006534-200111000-00045]
- DeBlois, C., Cote, M.F., Doillon, C.J., 1994. Heparin-fibroblast growth factor-fibrin complex: in vitro and in vivo applications to collagen-based materials. *Biomaterials*, **15**(9):665-672. [doi:10.1016/0142-9612(94)90164-3]
- Fasol, R., Schumacher, B., Schlaudraff, K., Hauenstein, K.H., Seitelberger, R., 1994. Experimental use of a modified fibrin glue to induce site-directed angiogenesis from the aorta to the heart. *J. Thorac. Cardiovasc. Surg.*, **107**(6):1432-1439.
- Germano, G., Kavanagh, P.B., Waechter, P., Areeda, J., van Kriekinge, S., Sharir, T., Lewin, H.C., Berman, D.S., 2000. A new algorithm for the quantitation of myocardial perfusion SPECT. I: technical principles and reproducibility. *J. Nucl. Med.*, **41**(4):712-719.
- Harada, K., Grossman, W., Friedman, M., Edelman, E.R., Prasad, P.V., Keighley, C.S., Manning, W.J., Sellke, F.W., Simons, M., 1994. Basic fibroblast growth factor improves myocardial function in chronically ischemic porcine hearts. *J. Clin. Invest.*, **94**(2):623-630. [doi:10.1172/JCI117378]
- Heilmann, C.A., Attmann, T., von Samson, P., Gobel, H., Marme, D., Beyersdorf, F., Lutter, G., 2003. Transmyocardial laser revascularization combined with vascular endothelial growth factor 121 (VEGF121) gene therapy for chronic myocardial ischemia—do the effects really add up? *Eur. J. Cardiothorac. Surg.*, **23**(1):74-80. [doi:10.1016/S1010-7940(02)00718-2]
- Henry, T.D., Annex, B.H., McKendall, G.R., Azrin, M.A., Lopez, J.J., Giordano, F.J., Shah, P.K., Willerson, J.T., Benza, R.L., Berman, D.S., et al., 2003. The VIVA trial: vascular endothelial growth factor in ischemia for vascular angiogenesis. *Circulation*, **107**(10):1359-1365. [doi:10.1161/01.CIR.0000061911.47710.8A]
- Henry, T.D., Grines, C.L., Watkins, M.W., Dib, N., Barbeau, G., Moreadith, R., Andrasfay, T., Engler, R.L., 2007. Effects of Ad5FGF-4 in patients with angina: an analysis of pooled data from the AGENT-3 and AGENT-4 trials. *J. Am. Coll. Cardiol.*, **50**(11):1038-1046. [doi:10.1016/j.jacc.2007.06.010]
- House, S.L., Bolte, C., Zhou, M., Doetschman, T., Klevitsky, R., Newman, G., Schultz Jel, J., 2003. Cardiac-specific overexpression of fibroblast growth factor-2 protects against myocardial dysfunction and infarction in a murine model of low-flow ischemia. *Circulation*, **108**(25):3140-3148. [doi:10.1161/01.CIR.0000105723.91637.1C]
- Hughes, G.C., Kypson, A.P., St. Louis, J.D., Annex, B.H., Coleman, R.E., DeGrado, T.R., Donovan, C.L., Lowe, J.E., Landolfo, K.P., 1999. Improved perfusion and contractile reserve after transmyocardial laser revascularization in a model of hibernating myocardium. *Ann. Thorac. Surg.*, **67**(6):1714-1720. [doi:10.1016/S0003-4975(99)00317-3]
- Iwakura, A., Fujita, M., Kataoka, K., Tambara, K., Sakakibara, Y., Komeda, M., Tabata, Y., 2003. Intramyocardial sustained delivery of basic fibroblast growth factor improves angiogenesis and ventricular function in a rat infarct model. *Heart Vessels*, **18**(2):93-99. [doi:10.1007/s10380-002-0686-5]
- Jeon, O., Ryu, S.H., Chung, J.H., Kim, B.S., 2005. Control of basic fibroblast growth factor release from fibrin gel with heparin and concentrations of fibrinogen and thrombin. *J. Control Release*, **105**(3):249-259. [doi:10.1016/j.jconrel.2005.03.023]
- Jiang, Z.S., Srisakuldee, W., Soulet, F., Bouche, G., Kardami, E., 2004. Non-angiogenic FGF-2 protects the ischemic heart from injury, in the presence or absence of reperfusion. *Cardiovasc. Res.*, **62**(1):154-166. [doi:10.1016/j.cardiores.2004.01.009]
- Kang, S.S., Gosselin, C., Ren, D., Greisler, H.P., 1995. Selective stimulation of endothelial cell proliferation with inhibition of smooth muscle cell proliferation by fibroblast growth factor-1 plus heparin delivered from fibrin glue suspensions. *Surgery*, **118**(2):280-287. [doi:10.1016/S0039-6060(05)80335-6]
- Karacal, N., Cobanoglu, U., Ambarcioglu, O., Kutlu, N., 2007. The effect of fibrin glue on fat graft survival. *J. Plast. Reconstr. Aesthet. Surg.*, **60**(3):300-303. [doi:10.1016/j.jbips.2006.03.051]
- Kastrup, J., Jorgensen, E., Ruck, A., Tagil, K., Glogar, D., Ruzyllo, W., Botker, H.E., Dudek, D., Drvota, V., Hesse, B., et al., 2005. Direct intramyocardial plasmid vascular endothelial growth factor-A165 gene therapy in patients with stable severe angina pectoris A randomized double-blind placebo-controlled study: the Euroinject One trial. *J. Am. Coll. Cardiol.*, **45**(7):982-988. [doi:10.1016/j.jacc.2004.12.068]
- Kawasuji, M., Nagamine, H., Ikeda, M., Sakakibara, N., Takemura, H., Fujii, S., Watanabe, Y., 2000. Therapeutic angiogenesis with intramyocardial administration of basic fibroblast growth factor. *Ann. Thorac. Surg.*, **69**(4):1155-1161. [doi:10.1016/S0003-4975(99)01557-X]
- Kornowski, R., Fuchs, S., Leon, M.B., Epstein, S.E., 2000a. Delivery strategies to achieve therapeutic myocardial angiogenesis. *Circulation*, **101**(4):454-458.
- Kornowski, R., Baim, D.S., Moses, J.W., Hong, M.K., Laham, R.J., Fuchs, S., Hendel, R.C., Wallace, D., Cohen, D.J., Bonow, R.O., et al., 2000b. Short- and intermediate-term clinical outcomes from direct myocardial laser revascularization guided by Biosense left ventricular electromechanical mapping. *Circulation*, **102**(10):1120-1125.
- Laham, R.J., Garcia, L., Baim, D.S., Post, M., Simons, M., 1999. Therapeutic angiogenesis using basic fibroblast

- growth factor and vascular endothelial growth factor using various delivery strategies. *Curr. Interv. Cardiol. Rep.*, **1**(3):228-233.
- Laham, R.J., Chronos, N.A., Pike, M., Leimbach, M.E., Udelson, J.E., Pearlman, J.D., Pettigrew, R.I., Whitehouse, M.J., Yoshizawa, C., Simons, M., 2000. Intracoronary basic fibroblast growth factor (FGF-2) in patients with severe ischemic heart disease: results of a phase I open-label dose escalation study. *J. Am. Coll. Cardiol.*, **36**(7):2132-2139. [doi:10.1016/S0735-1097(00)00988-8]
- Lopez, J.J., Edelman, E.R., Stamler, A., Hibberd, M.G., Prasad, P., Caputo, R.P., Carrozza, J.P., Douglas, P.S., Sellke, F.W., Simons, M., 1997. Basic fibroblast growth factor in a porcine model of chronic myocardial ischemia: a comparison of angiographic, echocardiographic and coronary flow parameters. *J. Pharmacol. Exp. Ther.*, **282**(1):385-390.
- Phelps, E.A., Garcia, A.J., 2009. Update on therapeutic vascularization strategies. *Regen. Med.*, **4**(1):65-80. [doi:10.2217/17460751.4.1.65]
- Post, M.J., Laham, R., Sellke, F.W., Simons, M., 2001. Therapeutic angiogenesis in cardiology using protein formulations. *Cardiovasc. Res.*, **49**(3):522-531. [doi:10.1016/S0008-6363(00)00216-9]
- Sahni, A., Odrjlin, T., Francis, C.W., 1998. Binding of basic fibroblast growth factor to fibrinogen and fibrin. *J. Biol. Chem.*, **273**(13):7554-7559. [doi:10.1074/jbc.273.13.7554]
- Sahni, A., Khorana, A.A., Baggs, R.B., Peng, H., Francis, C.W., 2006. FGF-2 binding to fibrin(ogen) is required for augmented angiogenesis. *Blood*, **107**(1):126-131. [doi:10.1182/blood-2005-06-2460]
- Shao, Z.Q., Takaji, K., Katayama, Y., Kunitomo, R., Sakaguchi, H., Lai, Z.F., Kawasuji, M., 2006. Effects of intramyocardial administration of slow-release basic fibroblast growth factor on angiogenesis and ventricular remodeling in a rat infarct model. *Circ. J.*, **70**(4):471-477. [doi:10.1253/circj.70.471]
- Simons, M., Annex, B.H., Laham, R.J., Kleiman, N., Henry, T., Dauerman, H., Udelson, J.E., Gervino, E.V., Pike, M., Whitehouse, M.J., et al., 2002. Pharmacological treatment of coronary artery disease with recombinant fibroblast growth factor-2: double-blind, randomized, controlled clinical trial. *Circulation*, **105**(7):788-793. [doi:10.1161/hc0802.104407]
- Stewart, D.J., Kutryk, M.J., Fitchett, D., Freeman, M., Camack, N., Su, Y., Della Siega, A., Bilodeau, L., Burton, J.R., Proulx, G., et al., 2009. VEGF gene therapy fails to improve perfusion of ischemic myocardium in patients with advanced coronary disease: results of the NORTHERN trial. *Mol. Ther.*, **17**(6):1109-1115. [doi:10.1038/mt.2009.70]
- Sutton, M.G., Sharpe, N., 2000. Left ventricular remodeling after myocardial infarction: pathophysiology and therapy. *Circulation*, **101**(25):2981-2988.
- Yamamoto, N., Kohmoto, T., Roethy, W., Gu, A., DeRosa, C., Rabbani, L.E., Smith, C.R., Burkhoff, D., 2000. Histologic evidence that basic fibroblast growth factor enhances the angiogenic effects of transmyocardial laser revascularization. *Basic Res. Cardiol.*, **95**(1):55-63. [doi:10.1007/s003950050008]

New Website, More Information in 2010

<http://www.zju.edu.cn/jzus>; <http://www.springerlink.com>




JOURNAL OF ZHEJIANG UNIVERSITY

SCIENCE ABC


- Home
- Current Issue
- Online Submission
- Readers Register
- Contact Us

Journals




Journal of Zhejiang University-SCIENCE A (Applied Physics & Engineering)
ISSNs 1673-565X (Print); 1862-1775 (Online); started in 2000, Monthly.

JZUS-A is an international "Applied Physics & Engineering" reviewed-Journal indexed by SCI-E, Ei Compendex, INSPEC, CA, SA, JST, AJ, ZM, CABI, ZR, CSA, etc. It mainly covers research in Applied Physics, Mechanical and Civil Engineering, Environmental Science and Energy, Materials Science and Chemical Engineering, etc.



Journal of Zhejiang University-SCIENCE B (Biomedicine & Biotechnology)
ISSNs 1673-1581 (Print); 1862-1783 (Online); started in 2005, Monthly.

JZUS-B is an international "Biomedicine & Biotechnology" reviewed-Journal indexed by SCI-E, MEDLINE, PMC, BA, BIOSIS Previews, JST, ZR, CA, SA, AJ, ZM, CABI, CSA, etc., and supported by the National Natural Science Foundation of China. It mainly covers research in Biomedicine, Biochemistry and Biotechnology, etc.



Journal of Zhejiang University-SCIENCE C (Computers & Electronics)
ISSNs 1869-1951 (Print); 1869-196X (Online); starts in 2010, Monthly.

JZUS-C is an international "Computers & Electronics" reviewed-Journal indexed by SCI-E, Ei Compendex, DBLP, IC, Scopus, JST, CSA, etc. It covers research in Computer Science, Electrical and Electronic Engineering, Information Sciences, Automation, Control, Telecommunications, as well as Applied Mathematics related to Computer Science.

* In the Web of Science, search for "JOURNAL OF ZHEJIANG UNIVERSITY-SCIENCE C"

NEWS: In 2009 JCR of Thomson Reuters, the Impact Factor of JZUS-A is 0.301, and the Impact Factor of JZUS-B is 1.041

Top 10 cited A B

Hybrid discrete particle sw...

How to realize a negative r...

Antioxidant power of phytoc...

Three-dimensional analysis ...

THE POLYMERIZATION OF METHY...

[more](#)

Newest cited A B C

Free vibration of pre-tensl...

Detecting stable phase stru...

Critical review in adsorpti...

Low-cost sensorless control...

Optimal operating policy fo...

[more](#)

Top 10 DOIs Monthly

Model-based testing with UM...

Experimental study of light...

Heat shock protein 90 prote...

Body mass index, waist circ...

Over-expression of the A...

[more](#)

Newest 10 comments

Charge dynamic characterist...

Optimal choice of parameter...

Synthesis of arbutin by tun...