



## Unilateral hemilaminectomy for patients with intradural extramedullary tumors

Cai-xing SUN<sup>1,2</sup>, Xu-li MENG<sup>†‡</sup>, Shang-nao XIE<sup>2</sup>, Yang YU<sup>2</sup>, Hong-jian YANG<sup>2</sup>, Bin WU<sup>2</sup>

(<sup>1</sup>Zhejiang Traditional Medical University, Hangzhou 310009, China)

(<sup>2</sup>Department of Neurooncology, Zhejiang Cancer Hospital, Hangzhou 310009, China)

<sup>†</sup>E-mail: mxlmail@126.com

Received Nov. 20, 2010; Revision accepted Apr. 25, 2011; Crosschecked June 12, 2011

**Abstract:** A modified hemilaminectomy was introduced in an attempt to explore the operative techniques and the values of the limited approach to spinal cord tumors. Forty-five consecutive patients with intradural extramedullary lesions, who underwent modified hemilaminectomy, were studied retrospectively. The intraspinal tumors were removed via the limited bone window with a 3.3-cm mean length (range: 2.0–6.5 cm) and a 1.2-cm mean width (range: 0.6–1.5 cm), in which the inner parts of the medial and lateral laminae were mostly undercut for wider view. Spinal lesions were cervical in 21 cases, thoracic in 12 cases, lumbar in 10 cases, and multiple in 2 cases. Forty-three cases were completely excised via hemilaminectomy alone. Two subjects with dumbbell neurinoma underwent two-stage tumor removal via anterolateral cervical approach following hemilaminectomy. With respect to neurological status, the percentage of good Frankel scale (D+E grade) was markedly improved from 22.2% on admission to 93.3% at follow-up. At the median 26-month follow-up evaluation by magnetic resonance imaging (MRI), none of the subjects showed spinal deformity or instability. By preserving musculoligamentous attachments and posterior bony elements as much as possible, the modified approach is minimally invasive and may be routinely used to remove intradural and extramedullary tumors, especially in patients with meningiomas and neurinomas.

**Key words:** Hemilaminectomy, Spinal cord tumors, Microsurgery

doi:10.1631/jzus.B1000402

Document code: A

CLC number: R739.4

### 1 Introduction

In China, the average ratio of brain to spinal cord tumors is 8:1, and the ratio of neurinomas to meningiomas is 3.8:1. This value is much higher than those found in western reports (almost 1:1), but is close to the ratio reported in the Japanese literature (3.9:1) (Cheng, 1982). Of the spinal cord tumors identified, 69% is non-malignant, and the most common histological types are meningiomas (29%), nerve sheath tumors (24%), and ependymomas (23%) by population-based data available on primary spinal cord (Schellinger *et al.*, 2008). The initial strategy for patients with spinal cord tumors is to surgically ex-

tirpate via different approaches, which includes laminectomy (Raimondi *et al.*, 1976; Yasuoka *et al.*, 1981; Alexander, 1985; Reimer and Onofrio, 1985; Lonstein, 1977), hemilaminectomy (Taylor, 1910; Panjabi and White, 1980; Abbott *et al.*, 1992; Öktem *et al.*, 2000; Ogden *et al.*, 2009), partial hemilaminectomy (Yasargil *et al.*, 1991), and osteoblastic laminotomy and osteoplastic laminotomy (Parkinson, 1977; Inoue *et al.*, 1996; Yeh *et al.*, 2001). Although the hemilaminectomy technique is known to neurosurgeons performing spinal surgery, conventional laminectomy has been commonly used for extirpation of spinal tumors. Clinical studies demonstrated that laminectomy might be associated with a number of postoperative complications, including spinal deformity, instability, epidural fibrosis, and progressive myelopathy (Raimondi *et al.*, 1976; Lonstein, 1977;

<sup>‡</sup> Corresponding author

Yasuoka *et al.*, 1981; Alexander, 1985; Reimer and Onofrio, 1985). Osteoblastic laminotomy and osteoplastic laminotomy remained desirable to rate the above-mentioned complications (Raimondi *et al.*, 1976; Parkinson, 1977; Inoue *et al.*, 1996; Yeh *et al.*, 2001).

Unilateral hemilaminectomy which was reported by Taylor (1910), was popularized by Eggert *et al.* (1983) and Chiou *et al.* (1989). Biomechanical studies demonstrated that a minimally-invasive hemilaminar exposure preserves the structural integrity of the lumbar spine and minimizes alterations to segmental motion postoperatively (Panjabi and White, 1980; Ogden, *et al.*, 2009). After the advent of computed tomography (CT) scan and magnetic resonance imaging (MRI) in neuroimaging evaluation, the concept of minimally invasive neurosurgery has been introduced and popularized by neurosurgeons in the century. In this study, we reported our 45 consecutive subjects with spinal cord lesions, who underwent the less invasive approach, in an attempt to explore the operative techniques and the values of the limited approach.

## 2 Subjects and methods

Between January 2003 and November 2009, 45 consecutive patients with intradural extramedullary lesions, who underwent a microsurgically unilateral hemilaminectomy for the resection of spinal tumors at our neurooncological department, have been studied. Subjects' demographics, operative reports, histological findings, pre- and postoperative images, and follow-up information were reviewed. Neurological statuses on admission and at follow-up were evaluated by Frankel grade classification (Frankel *et al.*, 1969). Contrast-enhanced MRI was used to demonstrate the side, size and location of the suspected tumor (Figs. 1a–1c and 2a–2b) in all cases. Magnetic resonance angiography (MRA) was used to determine the relationship between tumor and vertebral artery in four cases involving cervical spinal cord. Preoperative CT-scan was used to evaluate whether intervertebral foramen was enlarged or not. MRI was also reviewed to evaluate condition after removal of lesions (Figs. 1d–1f and 2c–2d). A postoperative CT-scan was used to show the extent of bone window (Figs. 1g, 1h, and 2e).

Unilateral hemilaminectomy, which is based on the keyhole concept, has been conducted routinely for the removal of all intradural extramedullary tumors. Regarding our surgical technique, the concise steps of the modified approach and the differences in comparison with the conventional hemilaminar approach (Öktem *et al.*, 2000) were as follows:

1. If level determination was required, water-capsule was usually put on the surface of the involved spinous process and repeated preoperative MRI underwent for precise localization (Figs. 1a and 1b). All subjects were operated in a prone position and under general anesthesia. The subjects with cervical spinal tumors were fixed in a three-point fashion of Mayfield frame. A 3–6 cm longitudinal midline incision was performed.

2. After completion of ipsilateral paraspinal muscle dissection and retraction, the surgical corridor was obtained by modified hemilaminectomy, in which the inner parts of the medial and lateral laminae were mostly drilled for wider view, and the bone window had a 3.3-cm mean length (range: 2.0–6.5 cm) and a 1.2-cm mean width (range: 0.6–1.5 cm). When laminae were extremely narrow, such as in management of thoracic tumors, the base of the spinous process and parts of the articular process and the pedicle (in combination with facetectomy) were removed for wider surgical vision (Figs. 1g, 1h, and 2e).

3. Inner parts of the laminae of the upper and lower arches were undercut in rare cases, because the completion of the above steps allowed sufficient access to the ipsilateral, and even contralateral nerve roots under operating microscope.

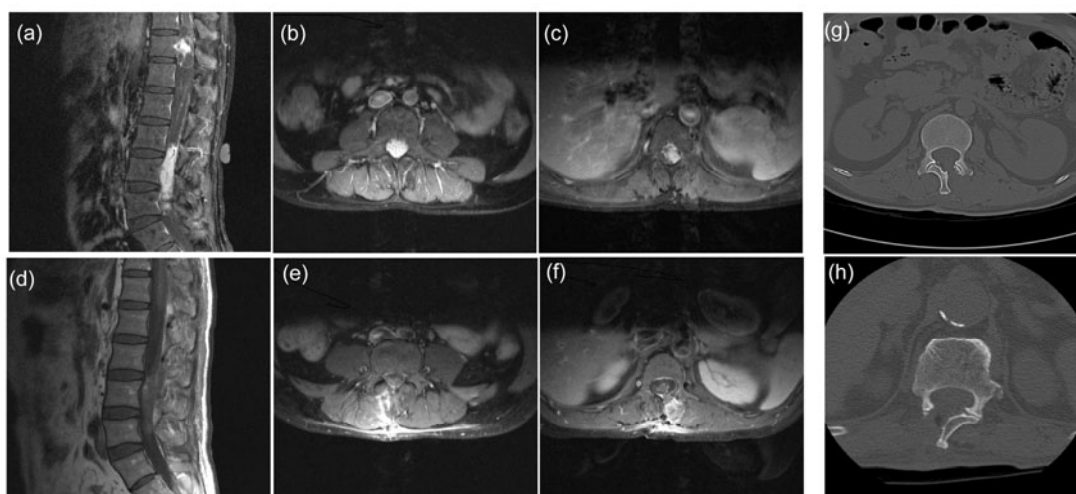
4. Ipsilateral nerve root or roots were not seen routinely before resection of tumor began.

5. Each tumor was removed in a piecemeal resection instead of en bloc resection in order to avoid damage to spinal cord as can as possible.

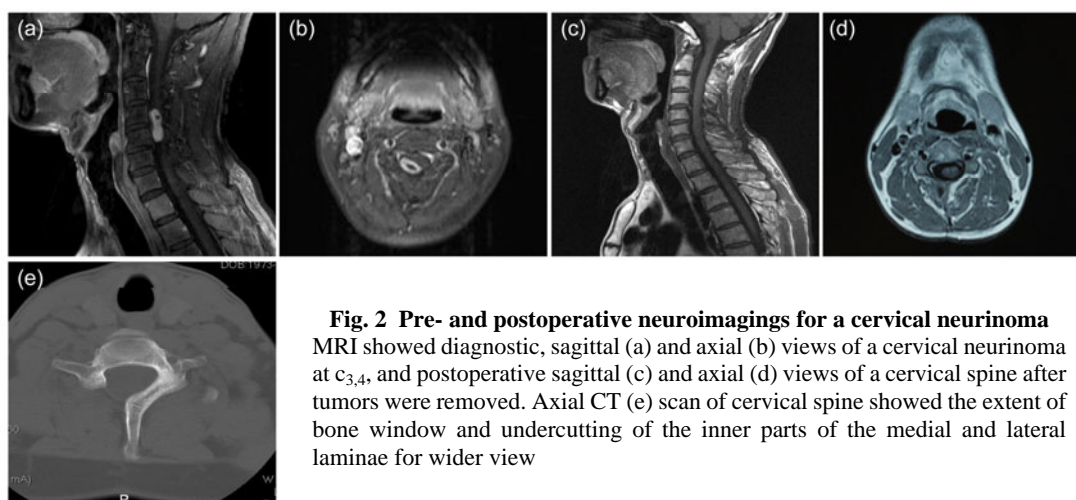
6. The dura was sutured in a water-tight fashion and followed by close reposition of posterior paraspinal muscle complex with interspinous ligaments.

## 3 Results

The study consisted of 26 females and 19 males with a median age of 47.5 years ranging from 30 to 72 years (mean (48.2±12.1) years). All complained of



**Fig. 1 Pre- and postoperative images for a patient with thoracic and lumbar spinal neurinomas**  
MRI showed diagnostic, preoperative sagittal (water-capsule marker for localization) (a) and axial views of the thoracic (b) and lumbar (c) spinal neurinomas at T12 and at L3–5 in the same patient, and postoperative sagittal (d) and axial views of thoracic (e) and lumbar (f) spines after tumors were removed. Axial CT scans of the thoracic (g) and lumbar (h) spines showed the extent of bone window and removals of the base of the spinous process and parts of the articular process and the pedicle for wider operative corridor



**Fig. 2 Pre- and postoperative neuroimaging for a cervical neurinoma**  
MRI showed diagnostic, sagittal (a) and axial (b) views of a cervical neurinoma at C<sub>3,4</sub>, and postoperative sagittal (c) and axial (d) views of a cervical spine after tumors were removed. Axial CT (e) scan of cervical spine showed the extent of bone window and undercutting of the inner parts of the medial and lateral laminae for wider view

local or radicular pain and sensory or motor disturbance of the extremities. Preoperative neurological examination showed weakness of the extremities in 40 cases, sensory disturbances in 33 cases, sphincter dysfunction in 2 cases, a lump in the neck in 2 cases, and a lump in the thoracic back in 1 case.

### 3.1 Location and histopathology of the lesions

In our series, there were 45 cases with 47 unilateral hemilaminectomies, and 50 tumors were excised. In two subjects with multiple neurinomas, 4 and 3 tumors were respectively removed. The location and operative histopathology of lesions were seen in Table 1. Spinal lesions were cervical in 21

cases, thoracic in 12 cases, lumbar in 10 cases, and multiple in 2 cases. Of four subjects with dumbbell neurinoma in cervical spine, two underwent simultaneous removal of the extradural component of tumor via enlarged intervertebral foramen following hemilaminectomy, two with huge cervical lumps underwent two-stage removal of tumor via anterolateral cervical approach following hemilaminectomy.

### 3.2 Early and late surgical results of the unilateral hemilaminectomy

All subjects succeeded in unilateral hemilaminectomy with no damage to spinal cord and vertebral artery. There was no leakage of cerebrospinal

fluid (CSF) or pseudo-meningocele. In the initial two cases, there were non-symptomatic epidural hydrops due to ignoring a close reposition of posterior paraspinal muscle complex with interspinous ligaments. One subject who had chronic B-typed hepatitis experienced postoperative bacterial fever and was healed after administration of sensitive antibiotics and constant drainage of CSF of lumbar cistern. Neurological status at follow-up evaluated by Frankel grade classification was seen in Table 2. Most of the subjects recovered to a better Frankel grade at the time of discharge. The percentage of good Frankel grade (the ratio of the number of subjects with D+E grade to all) was markedly improved from 22.2% on admission to 93.3% at follow-up. According to postoperative neuroimage evaluated by MRI, the stability of spine column was obtained (the condition in which kyphosis was found in cervical and lumbar spines was considered spinal instability). At the median 26-month (range: 4–94 months) follow-up evaluation, none of the subjects showed spinal deformity or spinal instability (Fig. 2c).

**Table 1 Location and histopathology of the lesions**

Location of tumor	Number of cases			Total
	EM	EN	DN	
Cervical	6	11	4	21
Thoracic	5	7	0	12
Lumbosacral	4	6	0	10
Multiple	0	2	0	2
Total	41	4	4	45

EM: extramedullary meningioma; EN: extramedullary neurinoma; DN: dumbbell-typed neurinoma

**Table 2 Neurological statuses on admission and at follow-up evaluated by Frankel grade classification**

Grade	Number of cases	
	Admission	Follow-up
A: No motor or sensory function below the level of injury	2	0
B: Some preserved sensory functions	16	1
C: Some preserved motor functions, unable to walk	17	2
D: Preserved useful motor functions, able to walk	8	23
E: Normal motor and sensory functions	2	19
Total	45	45

## 4 Discussion

The traditional approach to intraspinal lesions is laminectomy. The anatomical structures removed usually include the spinous process, the laminae, part of the facet complex, the interspinous and supraspinous ligaments, and the ligamentum flavum. It may result in gradually-increasing instability or deformity of the vertebral column (Raimondi *et al.*, 1976; Panjabi and White, 1980; Yasuoka *et al.*, 1981; Alexander, 1985; Reimer and Onofrio, 1985; Ogden *et al.*, 2009). In children, the rate of deformity after laminectomy is up to 88% with 27%–60% of subjects receiving a second fusion operation (de Jonge *et al.*, 2005; Yao *et al.*, 2007). However, in adults, there exist no sufficient studies which evaluate the rate of post-laminectomy deformity in the intradural tumor population. To reduce the post-laminectomy problems, less invasive procedures such as hemilaminectomy (Taylor, 1910; Panjabi and White, 1980; Abbott *et al.*, 1992; Öktem *et al.*, 2000; Ogden *et al.*, 2009) and osteoplastic laminotomy (Inoue *et al.*, 1996; Yeh *et al.*, 2001) have been proposed. However, with respect to prevention of kyphoscoliosis, there were no differences between laminectomy and osteoplastic laminotomy (Öktem *et al.*, 2000). Apparently, post-laminectomy kyphoscoliosis mostly attributes to over-damage to musculoligaments resulted from surgical stripping and denervation of the posterior paraspinal muscle complex rather than the reposition of laminae (Gros *et al.*, 1983; Yasargil *et al.*, 1991).

### 4.1 Rationale of unilateral hemilaminectomy and its modified approach

Denis (1983) firstly described the concept of the three-column spine for the explanation of instability of spinal trauma. Biomechanical and pathomechanical studies demonstrated that intact middle and posterior column structures were very critical to spinal stability (Lonstein, 1977; Panjabi and White, 1980; Ogden *et al.*, 2009). The rationale for hemilaminectomy and its modified approach (Koch-Wiewrodt *et al.*, 2007), which are less invasive and more limited, is to preserve the structures in spinal stability. The dorsal musculoligamentous attachments and posterior bony elements by hemilaminectomy, especially by its modified approach, are preserved as much as possible, and are injured less than by a conventional

laminectomy or by an osteoblastic laminectomy.

The advantages of the limited approach used in our series include following aspects: (1) it avoids damage to the dorsal structure as can as possible and preserves the structure of the three-column as much as possible; (2) it is consistent to the concept of minimally invasive neurosurgery, which is actively advocated by neurosurgeons in the century; and (3) postoperative patients may rapidly recovery and gain rehabilitation as early as possible without spinal deformity or instability. Therefore, the limited approach may be routinely used to manage the suitable patients with spinal cord tumors. In our series, the excellent early and late results demonstrated the advantages of the limited approach.

Recently, in an attempt to further reduce the need for bone removal, Koch-Wiewrodt *et al.* (2007) used multilevel interlaminar fenestration, also called "multiple spinal keyhole surgery", to remove intramedullary, extramedullary, or extradural lesions, and even some lesions that extended over several spine segments. Although this more limited approach required an endoscope or endoscopic assistance in a few cases, it seems that the more minimally-invasive technique would be popularized and known to neurosurgeons within the coming years.

#### 4.2 Technical requirements of the limited approach

The precise preoperative evaluation by MRI and localization could contribute to successful procedures. Intraoperative C-armed roentgenogram was mostly used to determine the vertebral level in the unilateral hemilaminectomy and osteoplastic laminotomy. In our experiences, repeated preoperative MRI by putting water-capsule maker on the surface of suspected spinous process was routinely obtained for precise localization. The surgical technique, the option of undercutting the contralateral lamina to increase exposure, has been described by Tredway *et al.* (2006). In our series, the inner parts of the medial and lateral laminae were mostly undercut for wider view. Under a condition such as narrow laminae for removal of thoracic tumors, the base of the spinous process and parts of the articular process and the pedicle (in combination with facetectomy) were removed to produce a wider surgical corridor. These maneuvers might preserve dorsal structures as much as possible. It is

emphasized that each tumor was removed piece by piece rather than en bloc to avoid damage to the spinal cord.

During operation, careful consideration should be taken to manage offending nerve root or roots and attachment of dura. It is hypothesized that chronic lesions may affect the function of offending nerves, and their function could be replaced by nearby nerve roots, so resection of offending nerves rarely brings about severe complications (Kim *et al.*, 1989; Klekamp and Samii, 1998). It is very difficult to extirpate the attachment of dura located ventrally via a narrow corridor of the limited approach. Resection of the attachment of dura may result in damage to anterior branches of nerve roots and spinal cord, and leakage of CSF. Patients with spinal meningiomas may experience recurrence of tumor. Boström *et al.* (2008) argued that the high rate of favorable clinical results combined with the low rate of recurrences supported the less invasive surgical concept, which did not aim for resection of the dural matrix of the spinal meningioma.

#### 4.3 Indications of the limited approach

The intradural extramedullary tumors located dorsal-laterally, ventral-laterally, laterally, and even ventrally, especially in patients with spinal neurinoma and meningioma could be removed via unilateral hemilaminectomy (Taylor, 1910; Panjabi and White, 1980; Abbott *et al.*, 1992; Öktem *et al.*, 2000; Ogden *et al.*, 2009) and osteoplastic laminotomy (Inoue *et al.*, 1996; Yeh *et al.*, 2001). Our modified maneuvers allowed sufficient access to the ipsilateral and contralateral nerve roots under operating microscope. To our knowledge, the indications of the modified approach are similar to those of unilateral hemilaminectomy.

Recently, some authors tried to remove intramedullary tumors via hemilaminectomy or partial hemilaminectomy (Chiou *et al.*, 1989; Yasargil *et al.*, 1991; Balak, 2008). Because of the fact that most of the patients with intramedullary tumors were young and the tumors were generally located in cervical and lumbar spines, in which the patients were prone to complicate with postoperative deformity and instability of spine, Chiou *et al.* (1989) argued that the feasibility of the hemilaminectomy should be considered in the management of intramedullary lesions. Yasargil *et al.* (1991) reported that extensive

intramedullary tumors could also be resected through this approach. Balak (2008) claimed that the approach permitted the surgeon to manipulate the intradural contralateral side easily, and emphasized the need to consider the hemilaminectomy technique in intraspinal tumor surgery. However, the spinal cord will be very fragile due to depression of slow-growing intramedullary lesions, and its function can be easily injured by any incorrect traction forces of the spinal cord. As necessary, complete laminectomy is recommended in handling intramedullary tumors (Chiou et al., 1989).

To preserve as much of the mechanically relevant bone structures and facet joints as possible in exploring neuromas with an intraforaminal component in the cervical spine, Banczerowski et al. (2009) used the hemi-semi-laminectomy combined with the supraforaminal burr hole technique in seven adult patients with neuroma extending inside the foramen in the region of the cervical spine. They claimed that under the operating microscope, the operating field was sufficient for tumor removal according to the keyhole concept and the modified surgical approach was suitable for exploring and removing neuromas located in the spinal canal and the neuroforamen.

In summary, the rationale of the keyhole hemilaminectomy is to avoid damage to the dorsal static structures of the vertebral column by preserving musculoligamentous attachments and posterior bony elements as much as possible. This modified approach is minimally invasive and could be routinely used for removal of intravertebral tumors, especially for meningiomas and neurinomas. However, with respect to management of intramedullary astrocytoma, the limited approach is prudent.

## References

- Abbott, R., Feldstein, N., Wisoff, N., Epstein, F.J., 1992. Osteoplastic laminotomy in children. *Pediatr. Neurosurg.*, **18**(3):153-156. [doi:10.1159/000120656]
- Alexander, E.Jr., 1985. Postlaminectomy Kyphosis. In: Wilkins, R.H., Rengachary, S.S. (Eds.), *Neurosurgery*. McGraw Hill, New York, p.2293-2297.
- Balak, N., 2008. Unilateral partial hemilaminectomy in the removal of a large spinal ependymoma: case report and technical review. *Spine J.*, **8**(6):1030-1036. [doi:10.1016/j.spinee.2007.07.001]
- Banczerowski, P., Veres, R., Vajda, J., 2009. Modified minimally invasive surgical approach to cervical neuromas with intraforaminal components: hemi-semi-laminectomy and supraforaminal burr hole (modified foraminotomy) technique. *Minim. Invasive Neurosurg.*, **52**(1):56-58. [doi:10.1055/s-0028-1104564]
- Boström, A., Burgel, U., Reinacher, P., 2008. A less invasive surgical concept for the resection of spinal meningiomas. *Acta Neurochir.*, **150**(6):551-556. [doi:10.1007/s00701-008-1514-0]
- Cheng, M.K., 1982. Spinal cord tumors in the People's Republic of China: a statistical review. *Neurosurgery*, **10**(1):22-24. [doi:10.1227/00006123-198201000-00004]
- Chiou, S.M., Eggert, H.R., Laborde, E.G., Seeger, W., 1989. Microsurgical unilateral approaches for spinal tumor surgery: eight years' experience in 256 primary operated patients. *Acta Neurochir.*, **100**(3-4):127-133. [doi:10.1007/BF01403599]
- de Jonge, T., Slullitel, H., Dubousset, J., Miladi, L., Wicart, P., Illes, T., 2005. Late-onset spinal deformities in children treated by laminectomy and radiation therapy for malignant tumors. *Eur. Spine J.*, **14**(8):765-771. [doi:10.1007/s00586-004-0778-1]
- Denis, F., 1983. The three column spine and its significance in the classification of acute thoracolumbar injuries spinal. *Spine*, **8**(8):817. [doi:10.1097/00007632-198311000-00003]
- Eggert, H.R., Scheremet, R., Seeger, W., Gaitzsch, J., 1983. Unilateral microsurgical approaches to extramedullary spinal tumors. Operative technique and results. *Acta Neurochir.*, **67**(3-4):245-253. [doi:10.1007/BF01401426]
- Frankel, H.L., Hancock, D.O., Hyslop, G., Melzak, J., Michaelis, L.S., Ungar, G.H., Vernon, J.D., Walsh, J.J., 1969. The value of postural reduction in the initial management of closed injuries of the spine with paraplegia and tetraplegia. I. *Paraplegia*, **7**(3):179-192. [doi:10.1038/sc.1969.30]
- Gros, C., Frerebeau, P., Privat, J.M., Benezech, J., Guillen, M., 1983. Laminectomies conservatrices lombaires. Technique et resultats. *Neurochirurgie*, **29**(2):207-225 (in Germany).
- Inoue, A., Ikata, T., Katoh, S., 1996. Spinal deformity following surgery for spinal cord tumors and tumorous lesions: analysis based on an assessment of the spinal functional curve. *Spinal Cord*, **34**(9):536-542. [doi:10.1038/sc.1996.97]
- Kim, P., Ebersold, M.J., Quast, L.M., 1989. Surgery of spinal nerve schwannoma. *J. Neurosurg.*, **71**(6):810-814.
- Klekamp, J., Samii, M., 1998. Surgery of spinal nerve sheath tumors with special reference to neurofibromatosis. *Neurosurgery*, **42**(2):279-290. [doi:10.1097/00006123-199802000-00042]
- Koch-Wiewrodt, D., Wagner, W., Perneczky, A., 2007. Unilateral multilevel interlaminar fenestration instead of laminectomy or hemilaminectomy: an alternative surgical approach to intraspinal space-occupying lesions. *J. Neurosurg. Spine*, **6**(5):485-492. [doi:10.3171/spi.2007.6.5.485]
- Lonstein, J.E., 1977. Post-laminectomy kyphosis. *Clin. Orthop.*, **128**(1):93-100.
- Ogden, A.T., Bresnahan, L., Smith, J.S., Natarajan, R., Fessler, R.G., 2009. Biomechanical comparison of traditional and

- minimally invasive intradural tumor exposures using finite element analysis. *Clin. Biomech.*, **24**(2):143-147. [doi:10.1016/j.clinbiomech.2008.11.005]
- Öktem, I.S., Akdemir, H., Kurtsoy, A., Koc, R.K., Menku, A., Tucer, B., 2000. Hemilaminectomy for the removal of the spinal lesions. *Spinal Cord.*, **38**(2):92-96. [doi:10.1038/sj.sc.3100963]
- Panjabi, M.M., White, A.A.III, 1980. Basic biomechanics of the spine. *Neurosurgery*, **7**(1):76-93. [doi:10.1227/00006123-198007000-00014]
- Parkinson, D., 1977. Replacement laminotomy. *Surg. Neurol.*, **8**(2):277-279.
- Raimondi, A.J., Gutierrez, F.A., Rocco, C.D., 1976. Laminotomy and total reconstruction of the posterior spinal arch for spinal canal surgery in childhood. *J. Neurosurg.*, **45**(5):555-560.
- Reimer, R., Onofrio, B.M., 1985. Astrocytomas of the spinal cord in children and adolescents. *J. Neurosurg.*, **63**(5):669-675.
- Schellinger, K.A., Propp, J.M., Villano, J.L., McCarthy, B.J., 2008. Descriptive epidemiology of primary spinal cord tumors. *J. Neurooncol.*, **87**(2):173-179. [doi:10.1007/s11060-007-9507-z]
- Taylor, A.S., 1910. Unilateral laminectomy. *Ann. Surg.*, **51**(4):529-533. [doi:10.1097/00006658-191004000-00010]
- Tredway, T.L., Santiago, P., Hrubes, M.R., Song, J.K., Christie, S.D., Fessler, R.G., 2006. Minimally invasive resection of intradural-extramedullary spinal neoplasms. *Neurosurgery*, **58**(1 Suppl.):52-58.
- Yao, K.C., McGirt, M.J., Chaichana, K.L., Constantini, S., Jallo, G.I., 2007. Risk factors for progressive spinal deformity following resection of intramedullary spinal cord tumors in children: an analysis of 161 consecutive cases. *J. Neurosurg.*, **107**(6 Suppl.):463-468.
- Yasargil, M.G., Tranmer, B.I., Adamson, T.E., Roth, P., 1991. Unilateral Partial Hemilaminectomy for the Removal of Extra- and Intramedullary Tumors and AVMs. In: Symon, L. (Ed.), *Advances and Technical Standards in Neurosurgery*. Springer, Wien, New York, p.113-132.
- Yasuoka, S., Hamlet, A.P., Laws, E.R., MacCarty, C.S., 1981. Pathogenesis and prophylaxis of postlaminectomy deformity of spine after multiple level laminectomy: difference between children and adults. *Neurosurgery*, **9**(2):145-152. [doi:10.1227/00006123-198108000-00006]
- Yeh, J.S., Sgouros, S., Walsh, A.R., Hockley, A.D., 2001. Spinal sagittal malalignment following surgery for primary intramedullary tumors in children. *Pediatr. Neurosurg.*, **35**(6):318-324. [doi:10.1159/000050444]