



Journal of Zhejiang University-SCIENCE B (Biomedicine & Biotechnology)  
ISSN 1673-1581 (Print); ISSN 1862-1783 (Online)  
www.zju.edu.cn/jzus; www.springerlink.com  
E-mail: jzus@zju.edu.cn



## Case report:

# Satisfactory clinical outcome following delayed repositioning of a traumatic post-LASIK flap with dislocation and shrinkage managed by irrigation, stretching, and debridement\*

Ye-sheng XU, Wen-jia XIE, Yu-feng YAO<sup>‡</sup>

(Department of Ophthalmology, Sir Run Run Shaw Hospital, School of Medicine, Zhejiang University, Hangzhou 310016, China)

<sup>†</sup>E-mail: yaoyf@zju.edu.cn

Received Sept. 1, 2016; Revision accepted Nov. 10, 2016; Crosschecked May 10, 2017

**Abstract:** Objective: To report surgical management and favorable outcome in a case with delayed repair of traumatic laser in situ keratomileusis (LASIK) flap dislocation with shrinkage and folds. Methods: A 30-year-old man with a five-year history of bilateral LASIK experienced blunt trauma to his right eye followed by decreased vision for 5 weeks. The surgical management included initially softening the flap by irrigation with balanced salt solution (BSS). The shrinkage folds were carefully and gently stretched by scraping with a 26-gauge cannula accompanied by BSS irrigation. All of the epithelial ingrowth on the flap inner surface and on the bed was thoroughly debrided by scraping and irrigation. After the flap was repositioned to match its original margin, a soft bandage contact lens was placed. Results: At his initial visit, slit-lamp microscopy and optical coherence tomography (OCT) showed shrinkage of the LASIK flap with an elevated margin approximately 3 mm above the original position. The flap covered half of the pupil and had multiple horizontal folds. Two months after surgery, the flap remained well positioned with only faint streaks in the anterior stroma. The uncorrected visual acuity of the right eye was 20/20 with a manifest refraction of Plano. Conclusions: For delayed repair of traumatically dislocated LASIK flaps, sufficient softening by BSS, stretching the shrinkage folds, and thorough debridement of ingrowth epithelium enable resetting the flap and provide satisfactory results.

**Key words:** Delayed repositioning; Laser in situ keratomileusis (LASIK); Traumatic flap dislocation  
<http://dx.doi.org/10.1631/jzus.B1600363>

**CLC number:** R779.62

## 1 Introduction

Laser in situ keratomileusis (LASIK), which utilizes a mechanical microkeratome to create a flap and then an excimer laser to abrade the corneal stroma, is currently the most popular corneal refractive surgery worldwide to correct myopia (Pallikaris *et al.*, 1991). However, a drawback of LASIK that can occur is poor wound healing between the flap and the stromal bed (Dawson *et al.*, 2005). Even 10 years or more after LASIK surgery, an inadvertent blunt trauma can cause dislocation of the flap (Holt *et al.*,

2012). Commonly, traumatic dislocation of the post-LASIK flap is an emergency and needs a surgeon to reposition the flap, the sooner the better (Melki *et al.*, 2000; Landau *et al.*, 2006). In the literature, there are reports of surgical management of post-LASIK flap dislocation that was delayed one or more weeks after the trauma (Kim and Silverman, 2010). We herein report a 5-week delay of a traumatic post-LASIK flap dislocation that had undergone shrinkage and developed multiple folds. The dislocated flap was successfully repositioned by softening the flap through irrigation with balanced salt solution (BSS), gentle stretching, and thoroughly debriding the ingrowth epithelium under the flap. The post-operative recovery was even and the visual acuity outcome was satisfactory.

<sup>‡</sup> Corresponding author

\* Project supported by the Zhejiang Provincial Department of Education (No. Y201533941), China

ORCID: Yu-feng YAO, <http://orcid.org/0000-0003-1494-9711>

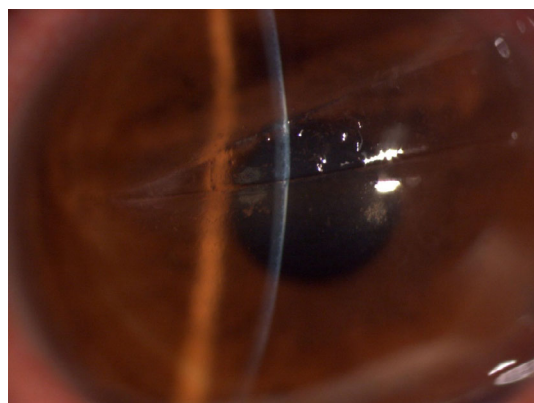
© Zhejiang University and Springer-Verlag Berlin Heidelberg 2017

## 2 Case report

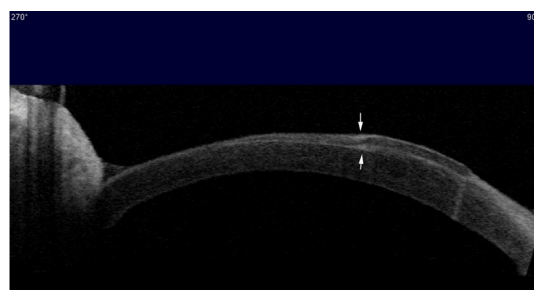
A 30-year-old man was referred to us from his local community health center due to decreased vision over a period of five weeks after he was struck in his right eye by a wooden stick. He had a history of uneventful bilateral LASIK five years ago at an outside hospital, but details of the surgical procedure were not provided. His local community clinic reported that he experienced blurry vision, pain, irritation, and photophobia in his right eye during his first visit. His primary care physician made a diagnosis of keratitis secondary to ocular trauma and prescribed a daily intravenous antibiotic injection for five weeks.

When the patient presented to our department five weeks after the original injury, his intensive ocular discomfort had been alleviated but his vision had not recovered. His right eye manifested uncorrected visual acuity of 20/100, and the best corrected visual acuity was 20/40 with a manifest refraction of  $-1.00 -2.00 \times 115$ . Slit-lamp microscopy revealed a flap with an elevated margin approximately 3 mm above the original position and covering half of the pupil. The flap exhibited vertical shrinkage and multiple folds. The edge of the flap was dislocated between the 2 and 9 o'clock positions, and the exposed stroma of the bed had been fully epithelialized based on fluorescein staining. A severe epithelial ingrowth on the bed under the flap was also suspected based on slit-lamp microscopy (Fig. 1). Anterior segment optical coherence tomography (OCT; Visante OCT, Carl Zeiss Meditec, Germany) showed the epithelial hyperplasia along and under the flap fold (Fig. 2, arrows), and stromal edema was also observed around the corresponding area of epithelial ingrowth.

Under topical anesthesia, we gently lifted the shrunken flap by a Sinsky hook through its margin and then carefully delaminated it (Fig. 3a). The lifted corneal flap involved over 200 degrees and had multiple adhered folds that prevented its stretching (Fig. 3b). The flap, together with its folds, was softened by irrigating both the surface and the underside of the flap with BSS. The folds of the corneal flap were carefully and gently stretched through mechanical scraping with a 26-gauge cannula by constant irrigation with BSS. The ingrown epithelium on the inner surface of the flap and on the stromal bed was carefully and thoroughly debrided by mechanical scraping



**Fig. 1** Punctate epithelial ingrowth was present under the flap at the central cornea

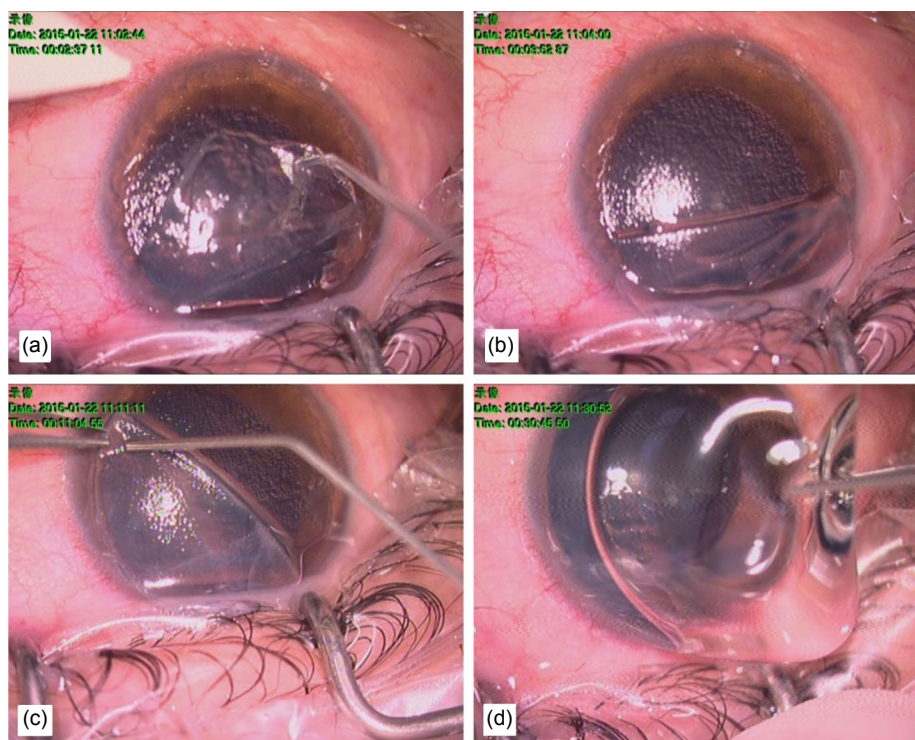


**Fig. 2** Anterior segment optical coherence tomography showed the epithelial hyperplasia along and under the flap fold (arrows)

Stromal edema was also present in the area corresponding to the epithelial ingrowth

and BSS irrigation (Fig. 3c). After sufficient stretching of the flap and thorough debridement of the ingrowth epithelium were confirmed under surgical microscopy, the flap was repositioned to match the original margin. A bandage contact lens was then applied (Fig. 3d). TobraDex eye ointment (containing 0.1% (1 g/L) dexamethasone and 0.3% (3 g/L) tobramycin; Alcon Laboratories, Fort Worth, TX, USA) was applied at the end of the surgery. After the surgery, 0.1% (1 g/L) fluorometholone eye drops (Santen Pharmaceutical Co., Osaka, Japan) four times daily and 0.5% (5 g/L) levofloxacin eye drops (Cravit; Santen, Osaka, Japan) four times daily for 7 d were instituted.

The scraped epithelial tissues from the inner surface of the flap and from the stromal bed were histologically identified as hyperplastic squamous epithelial cells. One day after surgery, the uncorrected visual acuity was 20/50, and there were moderate conjunctival injection and epithelial erosions on the flap. At the last visit 2 months after repositioning, the



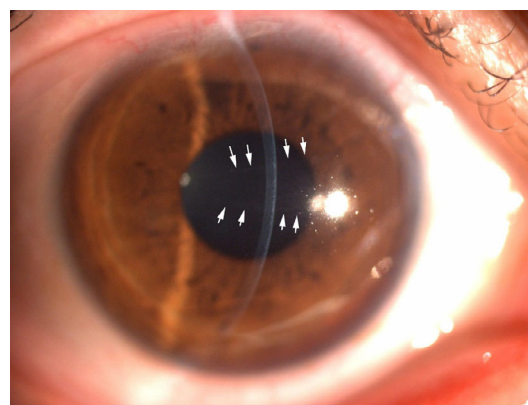**Fig. 3 Surgical procedures to reposition the dislocated flap**

(a) A Sinsky hook was used to remove the epithelium and to find the flap margin. (b) Approximately 200 degrees of the flap edge were separated and reflected. (c) The ingrown epithelium on the inner surface of the flap and on the bed was carefully and thoroughly debrided by a 26-gauge cannula and irrigation. (d) The flap was repositioned to match the original margin, and a bandage contact lens was placed

flap remained in a good position, except for faint streaks in the previous folds of the flap (Fig. 4, arrows). The clarity of the whole cornea was normal. The uncorrected visual acuity of the right eye was 20/20 with a manifest refraction of Plano.

### 3 Discussion

Previously reported cases of LASIK flap dislocation indicated that timely diagnosis and repositioning of the flap could result in an optimal visual outcome (Melki *et al.*, 2000; Nilforoushan *et al.*, 2005; Landau *et al.*, 2006). Soon after ocular trauma, the dislocated LASIK flap usually does not change in structure and is therefore easier to reposition. In contrast, delay in repositioning the flap in the bed may cause fibrosis and the development of scarring, cicatricial contracture, and subsequent fixed folds (Melki *et al.*, 2000; Nilforoushan *et al.*, 2005). Such scarring will result in stretching difficulty and unsuccessful repositioning of the flap.



**Fig. 4 Two months after surgical repair, the flap remained in a good position**

There were some faint streaks (arrows) where there were wrinkles in the dislocated flap

Davies and Randleman (2008) reported a case, in which the repair of a traumatic LASIK flap dislocation was delayed for 3 months, and there was partial loss of the flap tissue. Due to the inability to fully unfold the flap and also due to the presence of a partial tissue defect, they had to use three stitches of

interrupted 11-0 nylon sutures to secure the flap and to prevent the recurrent ingrowth of epithelium. Holt *et al.* (2012) reported repair of a mild flap dislocation after a delay of one month. While the flap had macrostriae, it did not have extensive folds and was successfully repositioned.

The ideal surgical procedure for delayed management of LASIK flap dislocation has not been fully established. Five weeks after our patient experienced ocular trauma, the flap was extensively dislocated and had multiple folds. Nevertheless, careful stretching of the flap under constant BSS irrigation and thorough debridement of the ingrown epithelium on the inner surface of the flap and on the stromal bed yielded a sufficiently good stretch for successfully repositioning the flap. Appropriate repositioning of the flap that provides a good match with its bed can prevent recurrence of epithelial ingrowth.

Because of the space created by a large flap fold, epithelial ingrowth is a common occurrence after delayed repositioning of a dislocated flap, especially when the interval between injury and repositioning is long (Cheng *et al.*, 2006). As shown in our case, epithelial ingrowth can occur on the inner surface of the flap, on the stromal bed surface, and in the fold areas. The invading hyperplastic epithelium can cause fixation of the flap folds. Thorough removal of such ingrowth epithelium is important to maintain the corneal clarity. While a sharp instrument can facilitate the removal, it can also cause damage to the stroma. We chose blunt debridement using a 26-gauge cannula assisted by constant irrigation with BSS. Patience and meticulousness are necessary to ensure the thorough removal of the ingrown epithelium. The result in our case demonstrated that these manipulations can ensure sufficient removal of the ingrown epithelium and prevent its recurrence after the flap has been repositioned. Although the ingrown epithelium under the flap and on the interface was carefully debrided, it was possible that some residual epithelial cells still existed between the flap and the bed. The non-recurrence of epithelial ingrowth in our case suggested that the residual epithelial cells might be the terminally differentiated cells. Without persistent epithelial cells migrating through the wound margin when the flap was perfectly matched with its original margin, the epithelial ingrowth could be terminated. Our case also showed that when the dislocated flap is

appropriately repositioned and ingrowth epithelium is prevented, the altered refraction caused by trauma complicated with flap dislocation can be mild, and postoperative visual acuity can be satisfactory.

In summary, patients who have a history of corneal refractive surgery are at higher risk for corneal complications following ocular trauma. A satisfactory clinical result can be achieved for delayed management of traumatic LASIK flap dislocation with large folds of the flap through three key manipulations: carefully stretching the flap, thoroughly debriding ingrown epithelium, and perfectly matching the flap with its original margin.

### Compliance with ethics guidelines

Ye-sheng XU, Wen-jia XIE, and Yu-feng YAO declare that they have no conflict of interest.

All procedures followed were in accordance with the ethical standards of the responsible committee on human experimentation (institutional and national) and with the Helsinki Declaration of 1975, as revised in 2008 (5). Informed consent was obtained from the patient for being included in the study.

### References

- Cheng, A.C., Rao, S.K., Leung, G.Y., *et al.*, 2006. Late traumatic flap dislocations after LASIK. *J. Refract. Surg.*, **22**(5):500-504.  
<http://dx.doi.org/10.3928/1081-597X-20060501-13>
- Davies, J.B., Randleman, J.B., 2008. Successful delayed surgical revision of a dislocated LASIK flap. *Ophthalmic Surg. Lasers Imag.*, **39**(3):221-224.  
<http://dx.doi.org/10.3928/15428877-20080501-05>
- Dawson, D.G., Kramer, T.R., Grossniklaus, H.E., *et al.*, 2005. Histologic, ultrastructural, and immunofluorescent evaluation of human laser-assisted in situ keratomileusis corneal wounds. *Arch. Ophthalmol.*, **123**(6):741-756.  
<http://dx.doi.org/10.1001/archoph.123.6.741>
- Holt, D.G., Sikder, S., Mifflin, M.D., 2012. Surgical management of traumatic LASIK flap dislocation with macrostriae and epithelial ingrowth 14 years postoperatively. *J. Cataract Refract. Surg.*, **38**(2):357-361.  
<http://dx.doi.org/10.1016/j.jcrs.2011.10.024>
- Kim, H.J., Silverman, C.M., 2010. Traumatic dislocation of LASIK flaps 4 and 9 years after surgery. *J. Refract. Surg.*, **26**(6):447-452.  
<http://dx.doi.org/10.3928/1081597X-20090710-03>
- Landau, D., Levy, J., Solomon, A., *et al.*, 2006. Traumatic corneal flap dislocation one to six years after LASIK in nine eyes with a favorable outcome. *J. Refract. Surg.*, **22**(9):884-889.  
<http://dx.doi.org/10.3928/1081-597X-20061101-08>
- Melki, S.A., Talamo, J.H., Demetriades, A.M., *et al.*, 2000. Late traumatic dislocation of laser in situ keratomileusis

- corneal flaps. *Ophthalmology*, **107**(12):2136-2139.  
[http://dx.doi.org/10.1016/S0161-6420\(00\)00405-X](http://dx.doi.org/10.1016/S0161-6420(00)00405-X)
- Nilforoushan, M.R., Speaker, M.G., Latkany, R., 2005. Traumatic flap dislocation 4 years after laser in situ keratomileusis. *J. Cataract Refract. Surg.*, **31**(8):1664-1665.  
<http://dx.doi.org/10.1016/j.jcrs.2005.01.022>
- Pallikaris, I.G., Papatzanaki, M.E., Siganos, D.S., et al., 1991. A corneal flap technique for laser in situ keratomileusis. Human studies. *Arch. Ophthalmol.*, **109**(12):1699-1702.  
<http://dx.doi.org/10.1001/archophth.1991.01080120083031>

## 中文概要

- 题目:** 冲洗伸展清创法处理延迟复位的 LASIK 术后外伤性瓣移位伴皱缩的良好临床结果
- 目的:** 报道一例手术处理延迟复位的准分子激光原位角膜磨镶术 (LASIK) 后瓣移位伴皱缩并取得良好

结果的案例。

**创新点:** 首次详细描述对延迟复位的 LASIK 术后瓣移位的手术方法。首次报道了长期延迟复位的 LASIK 术后瓣移位伴大皱缩经过无缝线的手术治疗也可取得良好的临床结果。

**方法:** 一例 30 岁男性在双眼 LASIK 术 5 年后受到右眼钝挫伤, 并延误治疗 5 周。手术方法包括平衡盐溶液软化角膜瓣, 仔细并轻柔地用 26G 针头刮除上皮和平衡盐溶液冲洗以伸展瓣皱褶。所有位于瓣内侧面和基质床的内生上皮都被仔细地刮除和冲洗去除。在复位角膜瓣后放置绷带式软性接触镜。

**结论:** 对于延迟处理的外伤性 LASIK 瓣移位, 通过平衡盐溶液充分软化角膜瓣、伸展瓣皱褶以及彻底清创内生上皮可将瓣复位并得到良好的临床结果。

**关键词:** 延迟复位; 准分子激光原位角膜磨镶术 (LASIK); 外伤性瓣移位