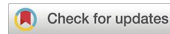



Review

<https://doi.org/10.1631/jzus.B2200589>



Biomarkers of malignant transformation in oral leukoplakia: from bench to bedside

Xinjia CAI^{1,3}, Jianyun ZHANG^{1,3}, Heyu ZHANG^{2,3}✉, Tiejun LI^{1,3}✉

¹Department of Oral Pathology, Peking University School and Hospital of Stomatology / National Center of Stomatology / National Clinical Research Center for Oral Diseases / National Engineering Research Center of Oral Biomaterials and Digital Medical Devices, Beijing 100081, China

²Central Laboratory, Peking University School and Hospital of Stomatology, Beijing 100081, China

³Research Unit of Precision Pathologic Diagnosis in Tumors of the Oral and Maxillofacial Regions, Chinese Academy of Medical Sciences (2019RU034), Beijing 100081, China

Abstract: Oral leukoplakia is a common precursor lesion of oral squamous cell carcinoma, which indicates a high potential of malignancy. The malignant transformation of oral leukoplakia seriously affects patient survival and quality of life; however, it is difficult to identify oral leukoplakia patients who will develop carcinoma because no biomarker exists to predict malignant transformation for effective clinical management. As a major problem in the field of head and neck pathologies, it is imperative to identify biomarkers of malignant transformation in oral leukoplakia. In this review, we discuss the potential biomarkers of malignant transformation reported in the literature and explore the translational probabilities from bench to bedside. Although no single biomarker has yet been applied in the clinical setting, profiling for genomic instability might be a promising adjunct.

Key words: Oral leukoplakia; Oral squamous cell carcinoma; Malignant transformation; Biomarker; Prognosis

1 Introduction

As a common oral potentially malignant disorder (OPMD), oral leukoplakia (OLK) has proven to increase the risk of oral squamous cell carcinoma (OSCC). It clinically manifests as a white plaque and is pathologically separated from other oral mucosal diseases (Warnakulasuriya et al., 2021). The worldwide prevalence of OLK is 4.1%, and the highest prevalence of 7.8% occurs among Asians (Mello et al., 2018). With a highly malignant potential, 9.8% of OLK progresses to OSCC (Aguirre-Urizar et al., 2021).

Various clinicopathological factors might be involved in the malignant transformation (MT) of OLK, such as sex, age, tobacco smoking, alcohol consumption,

oral epithelial dysplasia (OED), and systemic diseases (Aguirre-Urizar et al., 2021; Cai et al., 2021). However, so far, only OED has been considered to be a significant risk factor related to the MT of OLK. The risk of MT increases gradually with the severity of OED (Chaturvedi et al., 2020; Odell et al., 2021). However, because of the issues discussed below, the application of OED as a predictive factor of MT is limited. Multiple architectural and cytological features in OED diagnostic criteria were modified by the World Health Organization (WHO) in 2022 (Muller and Tilakaratne, 2022), while pathologists need to determine which features are classified as mild, moderate, or severe dysplasia in accordance with the three-tiered OED grading system. This subjective judgment has no quantitative biomarkers, resulting in poor repeatability and differing diagnoses made by pathologists (Odell et al., 2021; Pritzker et al., 2021; Peng JK et al., 2022). It has been reported that 39.6% of MT in OLK develops in patients without OED (Chaturvedi et al., 2020). The OED grading emphasizes the MT risk of moderate and severe dysplasias, but it has poor ability to indicate the risk of mild dysplasia, especially for OLK without

✉ Tiejun LI, litiejun22@vip.sina.com

Heyu ZHANG, zhangheyu1983@sina.cn

✉ Tiejun LI, <https://orcid.org/0000-0001-5983-2985>

Heyu ZHANG, <https://orcid.org/0000-0002-4461-2290>

Xinjia CAI, <https://orcid.org/0000-0002-3212-7474>

Received Nov. 20, 2022; Revision accepted Dec. 1, 2022;
Crosschecked May 8, 2023; Published online May 13, 2023

© Zhejiang University Press 2023

dysplasia. This is not conducive to clinical management, because OLK patients without dysplasia or with mild dysplasia cannot be excluded from an MT risk.

Therefore, biomarkers need to be developed to effectively identify the MT potential of OLK. Herein, we review the potential biomarkers of OLK and their clinical translation prospects. The exploration of biomarkers in terms of genes, cells, and microenvironments may contribute to improving the predictability of MT, the early identification of high-risk lesions, and reducing the burden of OSCC.

2 Cell proliferation and apoptosis biomarkers

OED in OLK is derived from the aberrant proliferation, maturation, and differentiation of mucosal epithelial cells. Further deterioration of these keratinocytes leads to OSCC development. Therefore, most studies have focused on molecules responsible for the alterations in epithelial cell proliferation and apoptosis (Table 1, Fig. 1), which have been mainly identified in the epithelial basal cell layer and adjacent areas.

Ki-67 is a common biomarker of cell proliferation. Its expression was gradually higher in normal control, OLK, and OSCC samples, but was not associated with OED severity (Lameira et al., 2014; Klein et al., 2020). Ki-67 staining was positive in most proliferative cells. The short renewal time of keratinocytes in normal oral mucosa because of the strong proliferative capacity of basal cells might interfere with immunohistochemical staining (Calenic et al., 2015). Therefore, Ki-67 staining is unable to estimate the malignancy risk of OLK. There was also insufficient evidence of an association between Ki-67 expression and the MT of OLK (Lameira et al., 2014). Minichromosome maintenance protein 3 (MCM3) is involved in the early replication of the eukaryotic genome and its increased expression has been found in normal tissue, OLK with mild OED, OLK with severe OED, and OSCC (Lameira et al., 2014). The expression of p27 decreases with the increasing severity of OED (Kovesi and Szende, 2006). Lameira et al. (2014) found that the ratio of MCM3/p27 expression might be a better marker than the ratio of Ki-67/p27 expression to evaluate cell proliferation and differentiation. Similar to Ki-67 expression, immunohistochemistry has

revealed the high expression of intermediate filament protein cytokeratin-8 (CK8) in OLK and OSCC (Gires et al., 2006), but no association was found between CK4, CK13, and cornulin expression and OLK or OSCC (Schaaij-Visser et al., 2010).

Cyclin D1 (CCND1) and p63 expression increases with the increasing severity of OED (Kovesi and Szende, 2006). CCND1 is a protein encoded by the *CCND1* gene on chromosome 11q13, which promotes cell cycle progression during the G1 phase. Meta-analysis has shown that CCND1 amplification and CCND1 overexpression were associated with a high risk of OSCC (relative risk (RR)=1.86, 95% confidence interval (CI)=1.13–3.06) (Ramos-García et al., 2019). Cyclin-dependent kinases (CDKs) bind to cyclins to regulate cell proliferation. CDK4 and CDK6 overexpression has been reported in OSCC, but only aberrant CDK4 expression was found in OLK with OED, and there was no association of CDK4 or CDK6 expression with OLK or OSCC, indicating that the overexpression of CDK4, but not CDK6, promotes OSCC development (Poomsawat et al., 2010). CCND1 and CDK4 overexpression in epithelial cells promotes aberrant cell cycle progression during G1/S transition, resulting in dysregulated cell proliferation and genomic instability that might lead to novel oncogenic events and subclones with an increased invasive capacity (Ramos-García et al., 2019).

The transforming growth factor- β (TGF- β) signaling pathway inhibits the progression of keratinocytes from G1 to S phase by forming complexes with two serine-threonine kinase receptors, T β RI and T β RII. The mothers against decapentaplegic homolog 7 (Smad7) blocks this signal by interfering with the activation of both Smad2 and Smad3 (Chen et al., 2013). Immunohistochemistry has revealed the aberrant expression of Smad2, Smad3, Smad4, phospho-Smad2 (p-Smad2), and p-Smad3 in both OLK and OSCC. In particular, Smad7 exhibits gradually increasing expression from normal oral mucosa, hyperplasia, mild OED, and moderate and severe OED to OSCC, demonstrating its potential as an MT biomarker (Chen et al., 2013). As an inhibitory Smad of the TGF- β pathway, Smad7 overexpression disrupts the balance of TGF- β signaling in keratinocytes (Chen et al., 2013). Moreover, the decreased expression of Smad4, another major regulatory molecule of TGF- β signaling, is associated with MT. Sakata et al. (2017) found that the downregulation of

Table 1 Biomarkers associated with the prognosis of oral leukoplakia

Type	Biomarker	Method	Study design	P value	Reference
Cell proliferation and apoptosis	Smad4	Immunohistochemistry	Retrospective single-center study	0.0017	Sakata et al., 2017
	p53	Immunohistochemistry	Retrospective single-center study		Cruz et al., 2002
	p53	Immunohistochemistry	Retrospective single-center study	<0.001	Zhang et al., 2017a
	p63	Immunohistochemistry	Retrospective single-center study	0.0007	Saintigny et al., 2009
Glucose-regulated protein 78	TGM3	Immunohistochemistry	Retrospective single-center study	0.0005	Wu et al., 2018
	Glucose-regulated protein 78	Western blot	Retrospective single-center study	0.002	Lin et al., 2010
	Podoplanin	Immunohistochemistry	Retrospective single-center study	<0.0005	de Vicente et al., 2013
	Podoplanin	Immunohistochemistry	Retrospective single-center study	0.0002	Kawaguchi et al., 2008
Cell adhesion and junction	Podoplanin	Immunohistochemistry	Retrospective single-center study	0.017	Monteiro et al., 2022
	LAMC2	Immunohistochemistry	Retrospective single-center study	0.002	Nguyen et al., 2017
	Axin2 and Snail	Immunohistochemistry	Retrospective single-center study	0.001	Zhang et al., 2017b
	S100A7	Immunohistochemistry	Retrospective single-center study	0.007	Kaur et al., 2014
Immune and inflammatory	CD68 and CD163	Immunohistochemistry	Retrospective single-center study	<0.05	Weber et al., 2020
	PD-1	Immunohistochemistry	Retrospective single-center study	<0.05	Xu et al., 2022
	LOH at 9p21 and 3p14	Microsatellite analyses	Retrospective single-center study	0.039	Mao et al., 1996
	LOH at 9p	Microsatellite analyses	Retrospective single-center study	<0.05	Graveland et al., 2013
Genomic instability	Copy number alterations	Whole-genome sequencing	Retrospective single-center study	<0.0001	Li et al., 2021
	DNA aneuploidy	DNA ploidy analysis	Retrospective single-center study	0.046	Sathasivam et al., 2021
	SOX2	Immunohistochemistry	Retrospective single-center study	0.01	de Vicente et al., 2019
	ALDH1 and CD133	Immunohistochemistry	Retrospective single-center study	0.001 and 0.002	Liu et al., 2013
Cancer stem cells	ABCG2 and BMI-1	Immunohistochemistry	Retrospective single-center study	0.011 and 0.003	Liu et al., 2012
	MicroRNAs	Whole-genome microRNA sequencing	Retrospective single-center study	<0.004	Philipone et al., 2016
	miR-208b-3p, miR-204-5p, miR-129-2-3p, and miR-3065-5p	Quantitative RT-PCR	Retrospective single-center study	0.038	Tu et al., 2022
	Salivary miR-375	Immunohistochemistry	Retrospective single-center study	0.015	Zhang et al., 2013
Others	CA9	Immunohistochemistry	Retrospective single-center study	<0.0001	Cao et al., 2011
	EZH2	Immunohistochemistry	Retrospective single-center study	<0.001	Baran et al., 2019
	MAGE-A	Immunohistochemistry	Retrospective single-center study		

Smad4: mothers against decapentaplegic homolog 4; TGM3: transglutaminase 3; LAMC2: laminin γ chain 2; CD68: cluster of differentiation 68; PD-1: programmed cell death protein-1; LOH: loss of heterozygosity; SOX2: sex-determining region Y-box 2; ALDH1: aldehyde dehydrogenase 1; ABCG2: adenosine triphosphate (ATP)-binding cassette, G2 subfamily; BMI-1: B lymphoma Mo-MLV insertion region-1 homolog; MIR: microRNA; CA9: carbonic anhydrase 9; EZH2: enhancer of zeste homolog 2; MAGE-A: melanoma-associated antigen-A; RT-PCR: reverse transcription-polymerase chain reaction.

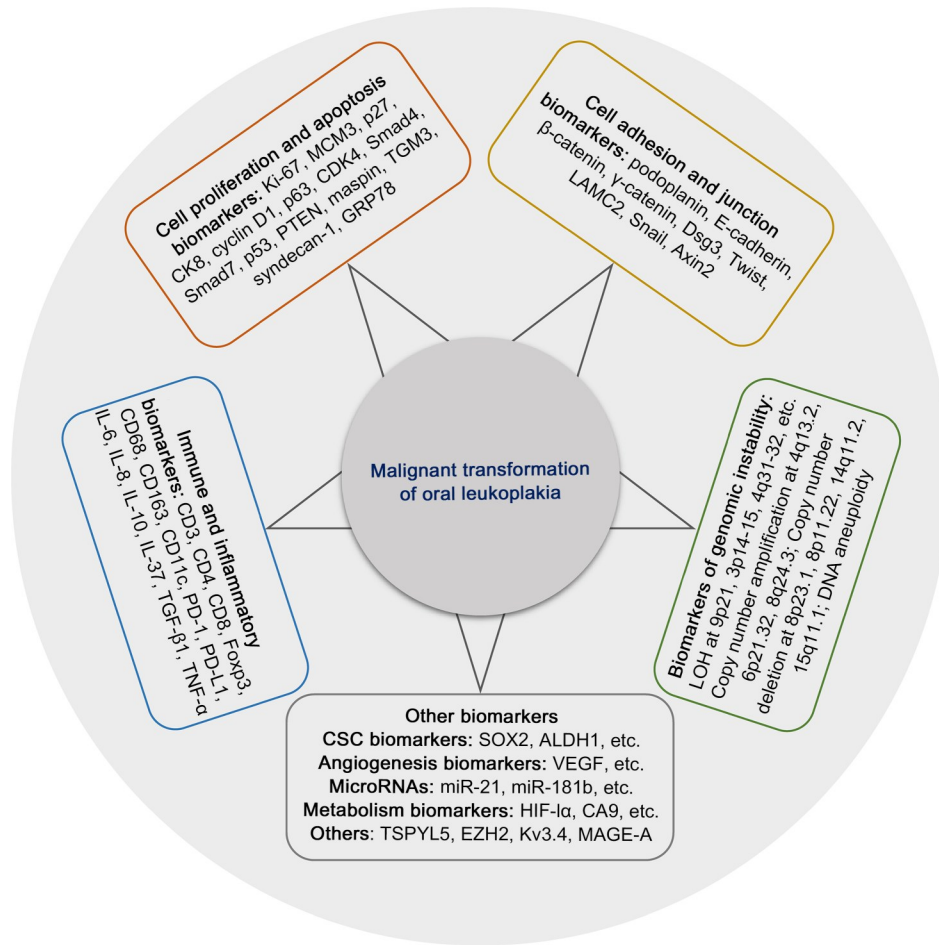


Fig. 1 Biomarkers of malignant transformation in oral leukoplakia. MCM3: minichromosome maintenance protein 3; CK8: cytokeratin-8; CDK4: cyclin-dependent kinase 4; PTEN: phosphatase and tensin homologue; TGM3: transglutaminase 3; GRP78: glucose regulatory protein 78; Dsg3: desmoglein 3; LAMC2: laminin gamma 2; LOH: loss of heterozygosity; SOX2: sex-determining region Y-box 2; ALDH1: aldehyde dehydrogenase 1; VEGF: vascular endothelial growth factor; HIF-1 α : hypoxia-inducible factor-1 α ; CA9: carbonic anhydrase 9; TSPYL5: testis-specific Y-encoded-like protein 5; EZH2: enhancer of zeste homolog 2; MAGE-A: melanoma-associated antigen-A; CD: cluster of differentiation; Foxp3: forkhead box P3; PD-1: programmed cell death protein-1; PD-L1: programmed cell death-ligand 1; IL: interleukin; TGF- β 1: transforming growth factor- β 1; TNF- α : tumor necrosis factor- α .

Smad4 increased the risk of MT (hazard ratio (HR)=2.632, 95% CI=1.031–7.654). Smad7 overexpression and reduced Smad4 expression suggested that TGF- β signaling plays a critical role in the MT of OLK.

The role of tumor suppressors in the MT of OLK has also attracted research interest. As one of the most typical tumor suppressors, mutation of tumor protein P53 (*TP53*, also known as *p53*) is an early event during OSCC progression. Positive staining of *p53* has been observed in basal and sub-basal epithelial layers of OLK, which was positively correlated with the OED grade (Wood et al., 1994; Cruz et al., 2002). A recent meta-analysis showed that *p53* overexpression was associated with the MT of OLK (RR=2.22, 95% CI=

1.35–3.64), which was independent of smoking and drinking habits or the OED grade (Ramos-García et al., 2022). Zhang et al. (2017a) constructed a nomogram model of MT in OLK with a C-index of 88% using immunohistochemical analysis of p53 and carbonic anhydrase 9 (CA9) combined with clinicopathological parameters, but there was no validation dataset. Phosphatase and tensin homologue (PTEN) is another typical tumor suppressor that inhibits phosphoinositide-3-kinase (PI3K) by the dephosphorylation of phosphatidylinositol 3,4,5-trisphosphate (PIP3) to regenerate phosphatidylinositol 4,5-bisphosphate (PIP2). Down-regulation of PTEN leads to the accumulation of PIP3, increased activation of PI3K and phosphorylated

protein kinase B (p-Akt), and the modulation of various downstream substrates involved in cancer progression. PTEN expression has also been observed in basal and sub-basal epithelial layers. It was found higher in OLK with moderate or severe OED and OSCC than in normal controls and in OLK with mild OED (Miyahara et al., 2018). Fluorescence in situ hybridization (FISH) revealed higher rates of allelic loss of PTEN in OSCC than in mild OED (Miyahara et al., 2018).

Tumor suppressor mammary serine protease inhibitor (maspin) is a member of the serine protease inhibitor superfamily of serpins located on chromosome 18q21.3. Maspin expression varies among the severities of OED and OSCC, and has been observed in the middle one-third of the epithelium in moderate and severe OED, and in the upper one-third of the epithelium in OSCC (Vered et al., 2009). Maspin expression correlates positively with p53, p63, and Ki-67, and might play a major role in OSCC development (Vered et al., 2009). As a tumor suppressor of OSCC, transglutaminase 3 (TGM3) has been associated with the OED grade of OLK, and the MT risk was significantly increased in OLK with a low expression of TGM3 (HR=5.045, 95% CI=1.686–15.097) (Wu et al., 2018). DNA hypermethylation in the promoter region of TGM3 might lead to its weak expression, and exogenous TGM3 inhibits cell proliferation and promotes apoptosis (Wu et al., 2018). Syndecan-1 expression decreases gradually from OLK concomitant with mild OED to moderate and severe OED, and is negatively associated with p53 and Ki-67 expression (Kurokawa et al., 2003). The glucose regulatory protein 78 (GRP78) expression has been positively correlated with the malignancy of OPMD and OSCC (Lin et al., 2010). GRP78 overexpression increases the recurrence risk and MT of OPMD (Lin et al., 2010). Additionally, GRP78 remains significantly associated with a high risk of MT in OPMD without OED (Lin et al., 2010).

3 Cell adhesion and junction biomarkers

Podoplanin is a mucin-like transmembrane glycoprotein expressed specifically in the endothelial cells of lymphatic vessels (de Vicente et al., 2013). Podoplanin expression has been observed in the basal epithelial cell layer of OLK, and both prospective and retrospective studies have found a positive correlation

of podoplanin expression with the severity of OED in OLK (Kawaguchi et al., 2008; de Vicente et al., 2013; Grochau et al., 2019). Overexpression of podoplanin has also been associated with an increased risk of MT in OLK (Kawaguchi et al., 2008; de Vicente et al., 2013; Monteiro et al., 2022). However, although podoplanin expression was associated with the MT of OLK by univariate analysis, the correlation was excluded when multivariate analysis was used (Kreppel et al., 2012). Saintigny et al. (2009) developed a group of biomarkers, including positive expression of p63, podoplanin, and intraepithelial inflammatory cell cluster, and found that the MT of OLK was significantly increased with a positive expression of the combined markers. Podoplanin is involved in the remodeling of actin cytoskeleton and promotes invasion by increasing cell motility. The MT of OLK might be associated with high podoplanin expression through increasing cell motility. It has also been reported that podoplanin induces epithelial–mesenchymal transition (EMT) by downregulating E-cadherin expression (de Vicente et al., 2013).

Compared with the normal epithelium, cell adhesion molecule profiles are different in OLK and OSCC. The cell membrane expression of desmoglein 3/ γ -catenin and E-cadherin/ β -catenin complexes is reduced in OLK and OSCC, and gradually shifts to weak cytoplasmic expression (Kyrodinou et al., 2014). Moreover, desmoglein 3 and γ -catenin expression correlates with the OED grade and OSCC differentiation (Kyrodinou et al., 2014). E-cadherin is expressed in basal and sub-basal cell layers in the normal oral mucosal epithelium, and it decreases gradually from normal epithelium, OLK with mild OED, and moderate and severe OED to OSCC (de Freitas Silva et al., 2014; von Zeidler et al., 2014). Twist promotes the loss of cell–cell adhesion through EMT, leading to increased cell motility. The expression of Twist has been found in basal cell cytoplasm, which gradually increased from normal mucosa, OLK with mild OED, moderate and severe OED to OSCC, and was negatively correlated with E-cadherin expression ($r=-0.512$, $P<0.001$) (de Freitas Silva et al., 2014). Laminin γ chain 2 (LAMC2) is a main component of the basement membrane and is associated with cell migration and invasion. LAMC2 expression in OSCC increases with the histopathological grade, and it correlates with the OED grade in OLK (Nguyen et al., 2017). Multivariate regression analysis revealed an 11-fold higher

risk of MT in OLK patients with LAMC2-positive expression (Nguyen et al., 2017).

Snail is a zinc-finger transcription repressor that activates the classical Wnt signaling pathway by inhibiting glycogen synthase kinase-3 (GSK-3) phosphorylation. As a downstream target of T-cell factor/lymphoid enhancer-binding factor (TCF/LEF) in the classical Wnt pathway, Axin2 increases nuclear Snail and β -catenin expression by regulating the shift in the nuclear and cytoplasmic localization of GSK-3. Snail expression is positively correlated with Axin2 in OLK, and the overexpression of both Snail and Axin2 increases the risk of MT in OLK (Zhang et al., 2017b). A nomogram model constructed by the immunohistochemical analysis of Snail and Axin2 as well as clinicopathological parameters, such as sex, age, and lesion sites, was used to predict the MT potential of OLK with a C-index of 0.76 (Zhang et al., 2017b). S100A7 overexpression has also been linked to the activation of non-classical Wnt pathway. Kaur et al. (2014) found that the positive expression of S100A7 in both the cytoplasm and nucleus was associated with an increased risk of MT in OLK (cytoplasm-positive expression odds ratio (OR)=3.970, 95% CI=1.5–10.2; nucleus-positive expression OR=3.929, 95% CI=1.2–12.4). A decrease in the cohesion and loss of adhesion of keratinocytes have been found in MT of OLK, resulting in cell proliferation and invasion. EMT changes the cell state to an invasive phenotype by silencing epithelial traits and promoting a stromal phenotype, which has been linked to the activation of Wnt signaling (von Zeidler et al., 2014; Zhang et al., 2017b). Therefore, biomarkers of intercellular adhesion and EMT might be potential predictors to identify the risk of MT.

4 Immune and inflammatory biomarkers

Comprehensive genomic and transcriptomic analyses have revealed more cluster of differentiation 4-positive ($CD4^+$) T cells and M1 macrophages, and higher cytotoxic T lymphocyte-associated antigen-4 (CTLA-4) expression in both OSCC and OLK than in normal controls (Ghosh et al., 2022). The number of $CD4^+$ T cells in OSCC was higher, while the abundance of $CD8^+$ T cells was lower than that in OLK (Ghosh et al., 2022). A study comparing the immunohistochemical staining of OLK with or without MT showed less $CD8^+$ T cell infiltration in MT samples

than in non-MT samples (Chaves et al., 2019). An alteration of the immune microenvironment might precede MT development in OLK. Three macrophage biomarkers (CD68, CD163, and CD11c) are significantly increased in the epithelial compartment of OLK with an MT potential (Weber et al., 2020). Furthermore, OLK with an MT potential showed an increase in the M2 polarization of macrophages (Weber et al., 2020). Bouaoud et al. (2021) found that three groups of independent M2 macrophage-related gene signatures were all related to the MT of OLK, and the area under the receiver operating characteristic (ROC) curve (AUC) of a Cox model constructed by these signatures to predict the MT risk was more than 80%. The increase of regulatory T cells, depletion of cytotoxic T lymphocytes, and increased infiltration of M2 macrophages might represent a pro-MT immune microenvironment in OLK. However, the potential of immune cell clusters as biomarkers of the MT risk needs to be verified by prospective studies.

The expression of programmed cell death protein-1 (PD-1) and the abundances of $CD3^+$, forkhead box P3-positive ($Foxp3^+$), and $CD8^+$ cells are higher in OLK with high-grade OED compared to low-grade OED (Xu et al., 2022). Furthermore, CD3, CD8, $Foxp3$, and programmed cell death-ligand 1 (PD-L1) overexpression has been found in OSCC (Xu et al., 2022). PD-1 expression has been positively correlated with CD3, CD8, and $Foxp3$ expression in OLK (Xu et al., 2022). The positive expression of PD-L1 was reported in non-smoking OLK patients and associated with an increased MT risk and shorter time to MT (Yagyuu et al., 2021). PD-1 and PD-L1 might induce immunosuppression in OLK and accelerate the progression of MT (Xu et al., 2022). Kujan et al. (2022) constructed a model using the integrated immunohistochemical score of PD-1, PD-L1, $Foxp3$, interleukin (IL)-6, IL-10, TGF- β 1, and tumor-infiltrating lymphocytes (TILs) to grade the OED of OLK with a sensitivity of 69.84% (56.98%–80.77%) and specificity of 89.95% (84.75%–93.84%). TILs might provide a microenvironment for the development of OED and the MT of OLK, reflecting the potential role of immune and proinflammatory factors in immune evasion during OSCC development (Kujan et al., 2022).

Proinflammatory factors and nuclear factor- κ B (NF- κ B)-dependent cytokines may be involved in the development of OLK and OSCC. Increased expression of IL-8 in saliva and tissue samples might be associated

with the MT of OLK, because IL-8 expression was found in 38% of OLK and 79% of OSCC, and no expression was observed in the normal mucosal epithelium (Babiuch et al., 2020). IL-6 and tumor necrosis factor- α (TNF- α) had higher levels in the saliva of OLK patients than in normal controls, but there was no significant association with MT (Brailo et al., 2006). High IL-37 expression has been observed in OLK and OSCC, localizing in cornified and spinous layers, which was associated with OED occurrence, but showed no difference between OLK and OSCC (Lin et al., 2016).

5 Biomarkers of genomic instability

The telomere is a cap structure in DNA that protects the ends of chromosomes. Telomeres gradually shorten with the division of somatic cells, and the shortening rate of telomeres might be related to cancer development. It has been found that OLK with short telomeres had a high risk of MT (Pal et al., 2022).

Loss of heterozygosity (LOH) is genomic deletion in a pair of chromosomes, ranging from a few thousands of nucleotides to the entire chromosome (Zhang and Rosin, 2001). The research methods of LOH include restriction fragment length polymorphism and microsatellite analyses. Because OLK samples are usually biopsy tissues, the samples are small with a low DNA content. Microsatellite analysis is a common method of LOH identification in OLK, requiring only a small amount of DNA to detect LOH on multiple chromosomes with high sensitivity (Zhang and Rosin, 2001).

High frequencies of polysomy in chromosomes 3 and 9 have been found in OLK with hyperplasia, which increased in OLK with OED, especially in chromosome 3, and showed a gradually rising trend in OLK with hyperplasia, OED, and carcinoma in situ to invasive OSCC (Schwarz et al., 2008). For specific loci, high frequencies of LOH at 9p21, 3p14–25, 4q31–32, and 17p12–14 have been reported in OLK, which were similar to the LOH patterns in the foci of early-stage MT progression (Jiang et al., 2001; Schwarz et al., 2008). The LOH at 9p21 might be related to the inactivation of p16, the LOH at 3p14–25 might be linked to an alteration of fragile histidine triad (*FHIT*), and the LOH at 17p13 has been associated with *p53*

mutation (Jiang et al., 2001). In addition, LOH or allelic imbalance of *PTEN* (10q23) and deleted in colorectal carcinoma (*DCC*) (18q21) as well as copy number alterations (CNAs) of epidermal growth factor receptor (*EGFR*), CDK inhibitor 2A (*CDKN2A*), and *CCND1* have been identified in OLK with OED and OSCC (Emilion et al., 1996; Chaves et al., 2020; Jäwert et al., 2022). CNAs include DNA deletion, amplification, and rearrangement due to chromosomal instability (Drews et al., 2022). Copy number amplifications at 4q13.2, 6p21.32, and 8q24.3, and copy number deletions at 8p23.1, 8p11.22, 14q11.2, and 15q11.1 are common genomic alterations in OLK and OSCC, which might be involved in MT progression (Bhosale et al., 2017). CNAs at 3p14 and 9p21 have been found to precede OSCC development. Moreover, an increased risk of MT has been demonstrated in OLK with more LOHs at 9p21 or 3p14 (Mao et al., 1996; Schwarz et al., 2008; Graveland et al., 2013). LOH occurrence might be related to the architectural features of OLK. LOH at 3p14.2 has been associated with irregular epithelial stratification, LOH at 9p22 might lead to drop-shaped rete ridges, and LOH at 17p13.1 has been correlated with premature keratinization (Fonseca-Silva et al., 2016).

Various unique patterns of allelic loss have been found in different lesions and at different anatomical sites in the same lesion of OLK, demonstrating the considerable inter- and intra-lesion heterogeneities of genetic alterations, which is independent of clinicopathological parameters (Gomes et al., 2015). Deletions of specific alleles might be random passenger events of genomic instability and be involved in cancer development, which are observed in premalignant lesions and the advanced stage of cancer progression (Partridge et al., 1998). Therefore, it has been suggested that the accumulation of genomic alteration events, rather than the sequence of a single molecular and genetic alteration, might be more relevant to cancer development (Partridge et al., 1998). OLK with more allele deletions has also been reported with a higher risk of MT than OLK with low-frequency allelic deletions (Partridge et al., 1998). We found by whole genome sequencing that the frequency of CNA events was positively associated with OED severity (Li et al., 2021). More CNA events have been indicated in OLK with a poor prognosis (Li et al., 2021). DNA aneuploidy is also considered to be a major biomarker of genomic instability and closely associated with the OED grade

(Sathasivam et al., 2021). The risk of aneuploid OLK was significantly higher, and DNA aneuploidy combined with OED severity predicted the MT potential of OLK (AUC=0.688, 95% CI=0.559–0.816) (Sathasivam et al., 2021).

6 Cancer stem cell biomarkers

OSCC development requires the gradual accumulation of multiple molecular events in cancer stem cells (CSCs). These cells have tissue specificity, slow division, and an unlimited self-renewal capability (Simple et al., 2015). Considering the malignant potential of OLK, CSC biomarkers might be involved in the MT of OLK. The sex-determining region Y-box 2 (SOX2) is located on chromosome 3q26, associated with the maintenance of pluripotency in embryonic stem cells, and involved in tumorigenesis. SOX2 expression was positively correlated with OED severity in OLK and linked to a higher risk of MT (HR=5.83, 95% CI=1.31–26.01) (de Vicente et al., 2019). Aldehyde dehydrogenase 1 (ALDH1) and CD133 are CSC biomarkers of OSCC and have been ascribed to prognostic value. The overexpression of ALDH1 (HR=4.17, 95% CI=1.96–8.90) and CD133 (HR=2.86, 95% CI=1.48–5.55) might increase the risk of MT and they were positively correlated with OLK (Liu et al., 2013). B lymphoma Mo-MLV insertion region 1 homolog (BMI-1) expression increases between OLK and OSCC and is positively related to Ki-67 expression (Klein et al., 2020). Liu et al. (2012) reported that BMI-1 and adenosine triphosphate (ATP)-binding cassette, G2 subfamily (ABCG2) overexpression was associated with an increased risk of MT.

7 Angiogenesis biomarkers

Angiogenesis is involved in the progression of OLK and OSCC. A gradually increasing microvascular density has been found from OLK with hyperkeratosis, mild OED, and moderate OED to OSCC by high-power microscopy (Thiem et al., 2017). Vascular endothelial growth factor (VEGF) is a major regulator of angiogenesis, and VEGF expression increases gradually with the severity of OED in OLK and OSCC (Thiem et al., 2017). Matrix metalloproteinase-9 (MMP-9) activates VEGF and participates in the neovascularization of tumor endothelial cells. The overexpression

of VEGF receptor 2 and MMP-9 is associated with OED severity, and further increased expression of MMP-9 has been found in OSCC (de Carvalho Fraga et al., 2014). MMP-9 might increase VEGF activity and is associated with pathological angiogenesis during tumorigenesis (de Carvalho Fraga et al., 2014).

8 MicroRNAs

As a kind of non-coding RNAs, the role of microRNAs (miRNAs) in OLK has also attracted widespread attention. MiRNA-21 (miR-21), miR-181b, and miR-345 expression increases gradually from normal oral mucosa, mild OED, moderate OED, and severe OED to OSCC, while miR-375 expression decreases gradually in this sequence (Cervigne et al., 2009; Tu et al., 2022). Through the sequencing analysis of saliva, plasma, and tissue samples, miR-10b, miR-31, miR-99b, miR-129-5p, miR-145, miR-150-5p, miR-181c, miR-222-3p, miR-339-5p, miR-423-5p, and miR-708 have been found to be involved in the MT of OLK (Yang et al., 2013; Maimaiti et al., 2015; Chang et al., 2018). Philipone et al. (2016) constructed a prediction model of MT in OLK using the expression of four miRNAs (miR-129-2-3p, miR-204-5p, miR-208b-3p, and miR-3065-5p) combined with the patient age and OED grade with an AUC of 0.792. The prediction performance of this model was better than that only including the OED grade (AUC=0.646). However, it was not externally validated, and patients with OLK with moderate or severe OED with a high risk of MT were not recruited for the model construction, which limited its application scope.

9 Others

Increased aerobic glycolysis is a typical characteristic of cancer (Cai et al., 2022a). Hypoxia-related proteins are involved in aerobic glycolysis. The expression of hypoxia-inducible factor-1 α (HIF-1 α) was higher in OLK with hyperplasia and OED than that in normal samples, and the expression of HIF-1 α -related protein glucose transporter-1 (Glut-1) as well as CA9 was also increased in OLK with OED (Zhang et al., 2013). Kaplan-Meier analysis showed that the overexpression of HIF-1 α , Glut-1, and CA9 was significantly associated with the MT of OLK with OED, but

only CA9 expression was a related risk factor for MT by multivariate Cox regression (HR=182.68, $P=0.015$) (Zhang et al., 2013). Moreover, OLK samples with MT showed the upregulation of all three proteins, whereas OLK without MT featured a low expression of all three proteins, suggesting that the combination of HIF-1 α , Glut-1, and CA9 expression may contribute to the prediction of OSCC development from OLK (Zhang et al., 2013).

Gene methylation increases in OLK with OED. Higher frequencies of methylation in testis-specific Y-encoded-like protein 5 (TSPYL5) have been found in OLK with OED and were negatively associated with OSCC differentiation (Abe et al., 2016). Enhancer of zeste homolog 2 (EZH2) is involved in the methylation process of genes and correlates with cell differentiation. EZH2 overexpression increased the MT risk in OLK, and no MT cases had OLK with a negative expression of EZH2 (Cao et al., 2011). Ion channels are transmembrane proteins that regulate ion flow across biofilms and carry out multiple physiological functions. The voltage-gated potassium channel Kv3.4 is a member of the Kv subfamily, which is also known as KCNC4, Shaw III, and Raw3, with functions in the transportation of potassium ions from the cell and depolarization of the cell membrane (Fernández-Valle et al., 2016). Kv3.4 expression is hardly found in the normal mucosal epithelium and gradually increases from OLK with hyperplasia to OED, which correlates positively with the grade of OSCC differentiation and might be involved in MT progression (Fernández-Valle et al., 2016). The expression of melanoma-associated antigen-A (MAGE-A) has been reported in oral and laryngeal squamous cell carcinoma, but not in healthy controls (Baran et al., 2019). MAGE-A expression was positively associated with the MT risk in OLK (Ries et al., 2012; Baran et al., 2019). A multi-marker prediction system developed by combining the expression of various MAGE-A-related genes showed a 100% positive and 83.5% negative predictive value of OLK carcinogenesis (Baran et al., 2019).

10 Current research limitations

During the conceptual evolution from “pre-malignant lesions” in 1978 to “oral potentially malignant disorders” in 2005, OLK has always been an important research topic of oral mucosal diseases associated

with OSCC (Warnakulasuriya et al., 2007, 2021). Different lines of the research progress from the initial single gene variation of the tumor suppressor *p53* to multiple gene combination biomarkers, such as cell proliferation and adhesion, from LOH at a single chromosome locus to genomic instability by whole genome sequencing, and from Formalin-embedded paraffin tissue samples to fresh frozen tissue and saliva as well as plasma samples, have represented the necessity and exploration potential of the clinical management of MT in OLK. However, decades after identifying the potential malignancy risk of OLK, upon reviewing studies on these biomarkers, there is still no biomarker available for clinical application to accurately predict the MT risk in OLK patients (Warnakulasuriya, 2000; Villa et al., 2019; Mello et al., 2020; Celentano et al., 2021; Monteiro et al., 2021).

Various factors limit the progression of MT biomarkers from bench to bedside. First, different types of OPMD are usually studied as a single entity; however, there are significant differences in the clinicopathological parameters and the malignancy risk among the different types of OPMD (Cai et al., 2019, 2021, 2022b). The molecular mechanisms of the pathogenesis and transformation of OLK, oral lichen planus (OLP), and oral submucous fibrosis (OSF) are different (Ray et al., 2019; Shao et al., 2019; William et al., 2021), which is also not conducive to the systematic review of evidence-based medicine (Villa et al., 2019). Second, the immunohistochemical evaluation of a single gene does not establish the malignancy risk of OLK. Most of the biomarkers reviewed here were assessed by immunohistochemistry, and various studies analyzing protein expression by different scoring systems might lead to different conclusions (Mello et al., 2020). The simple correlation between the negative/positive ratio of single gene expression and the malignancy rate is not sufficient to reveal biomarkers for MT prediction. Because the molecular heterogeneity of OLK and OSCC has been extensively studied, single gene biomarkers predicting the malignancy risk are considered neither sufficient nor necessary (Gomes et al., 2015; Mello et al., 2020; Celentano et al., 2021; Monteiro et al., 2021; van den Bossche et al., 2022). Third, biomarkers associated with the malignancy risk of OLK usually have a significant correlation with OED severity. Because of the high risk of MT in OLK concomitant with moderate and severe OED,

associations of these potential biomarkers with MT might be excluded from multivariate regression analysis. Biomarkers both independently associated with the OED grade and related to the MT risk might be more valuable. If not simultaneously, at least the biomarker should be associated with the MT risk in OLK independent of the OED grade (Mello et al., 2020; Monteiro et al., 2021). Finally, there is a lack of MT prediction models constructed from real-world data with large samples of longitudinal cohorts. Several reported biomarker models with a small number of samples (about 160 cases) were all performed using a single-center retrospective cohort without external validation cohorts, and certain models have been constructed using under-represented OLK samples (Philipone et al., 2016; Zhang et al., 2017a, 2017b; Weber et al., 2020; Bouaoud et al., 2021; Sathasivam et al., 2021; Tu et al., 2022).

11 Perspectives

Although not clinically available, reports of MT biomarkers in OLK have provided future research directions. For example, podoplanin expression and genomic instability, such as CNA and LOH, may be potential biomarkers of MT in OLK (Mello et al., 2020; Celentano et al., 2021; Monteiro et al., 2021). To further explore MT biomarkers in OLK, the following recommendations may contribute to their development. In accordance with the most recent WHO classification (Warnakulasuriya et al., 2021; Muller and Tilakaratne, 2022), the exploration of MT biomarkers needs to be performed in various types of OPMD with strict classification, and the associated risk factors, such as histopathological grading, lesion sites, and smoking and drinking habits, should be reported to the greatest extent possible. It is necessary to construct an MT model from longitudinal cohorts with many samples recruited from multiple centers that are externally validated, and a prospective study design might be optimal. Most OLK samples have been collected from biopsies with the inherent characteristic of a small tissue volume. The application of location-specific techniques such as laser capture microdissection can facilitate accurate material analysis. Moreover, emerging liquid biopsies acquire multiple fresh materials non-invasively by collecting saliva from the oral cavity, which might be the choice to collect large OLK samples. However, saliva is greatly

influenced by diet and the environment, and requires standardized treatment (Papale et al., 2022). The oral cavity is the window for interactions between the human body and the external environment. More than 700 kinds of microorganisms colonize the oral cavity (Peng X et al., 2022). Microorganisms, such as *Porphyromonas gingivalis* and *Fusobacterium nucleatum*, with differential abundances between OLK and OSCC, might be potent biomarkers (Pietrobon et al., 2021; Peng X et al., 2022). However, the current literature includes mainly comparative studies in this field, and the recruitment of a longitudinal cohort might be better to investigate the roles of microorganisms in the MT progression of OLK. Artificial intelligence (AI) might also assist with the diagnosis of OSCC and identify the transformation risk of OLK. Through deep learning and machine learning, the most relevant risk factors of MT can be screened from big data, which might play a role in biomarker identification (Ferrer-Sánchez et al., 2022; Tobias et al., 2022; Yang et al., 2022).

In summary, there is currently no solid evidence supporting the clinical translation of biomarkers to identify the risk of MT in patients with OLK. Therefore, multi-center integrated research including big data with long-term follow-ups as well as multi-omics is needed to promote translation from bench to bedside, that is, for precision medicine to manage OLK patients with a malignancy risk.

Acknowledgments

This work was supported by the National Natural Science Foundation of China (Nos. 81671006 and 81300894), the CAMS Innovation Fund for Medical Sciences (No. 2019-I2M-5-038), the National Clinical Key Discipline Construction Project (No. PKUSSNKP-202102), the Program for New Clinical Techniques and Therapies of Peking University Hospital of Stomatology (No. PKUSSNCT-22A14), and the Innovation Fund for Outstanding Doctoral Candidates of Peking University Health Science Center (No. BMU2022BSS001), China.

Author contributions

Tiejun LI and Heyu ZHANG: contributed to conception and design, and critically revised the manuscript. Xinjia CAI: contributed to conception, design, data acquisition and interpretation, and drafted the manuscript. Jianyun ZHANG: contributed to conception, data acquisition and interpretation, and drafted the manuscript. All authors have read and approved the final manuscript.

Compliance with ethics guidelines

Xinjia CAI, Jianyun ZHANG, Heyu ZHANG, and Tiejun LI declare that they have no conflict of interest.

This review does not contain any studies with human or animal subjects performed by any of the authors.

References

- Abe M, Yamashita S, Mori Y, et al., 2016. High-risk oral leukoplakia is associated with aberrant promoter methylation of multiple genes. *BMC Cancer*, 16:350. <https://doi.org/10.1186/s12885-016-2371-5>
- Aguirre-Urizar JM, Lafuente-Ibáñez de Mendoza I, Warnakulasuriya S, 2021. Malignant transformation of oral leukoplakia: systematic review and meta-analysis of the last 5 years. *Oral Dis*, 27(8):1881-1895. <https://doi.org/10.1111/odi.13810>
- Babiuch K, Kuśnierz-Cabala B, Kęsek B, et al., 2020. Evaluation of proinflammatory, NF-kappaB dependent cytokines: IL-1 α , IL-6, IL-8, and TNF- α in tissue specimens and saliva of patients with oral squamous cell carcinoma and oral potentially malignant disorders. *J Clin Med*, 9(3):867. <https://doi.org/10.3390/jcm9030867>
- Baran CA, Agaimy A, Wehrhan F, et al., 2019. MAGE-A expression in oral and laryngeal leukoplakia predicts malignant transformation. *Mod Pathol*, 32(8):1068-1081. <https://doi.org/10.1038/s41379-019-0253-5>
- Bhosale PG, Cristea S, Ambatipudi S, et al., 2017. Chromosomal alterations and gene expression changes associated with the progression of leukoplakia to advanced gingivobuccal cancer. *Transl Oncol*, 10(3):396-409. <https://doi.org/10.1016/j.tranon.2017.03.008>
- Bouaoud J, Foy JP, Tortereau A, et al., 2021. Early changes in the immune microenvironment of oral potentially malignant disorders reveal an unexpected association of M2 macrophages with oral cancer free survival. *Oncol Immunology*, 10(1):1944554. <https://doi.org/10.1080/2162402X.2021.1944554>
- Brailo V, Vučićević-Boras V, Cekić-Arambašin A, et al., 2006. The significance of salivary interleukin 6 and tumor necrosis factor alpha in patients with oral leukoplakia. *Oral Oncol*, 42(4):370-373. <https://doi.org/10.1016/j.oraloncology.2005.09.001>
- Cai XJ, Yao ZG, Liu G, et al., 2019. Oral submucous fibrosis: a clinicopathological study of 674 cases in China. *J Oral Pathol Med*, 48(4):321-325. <https://doi.org/10.1111/jop.12836>
- Cai XJ, Zhang JY, Han Y, et al., 2021. Development and validation of a nomogram prediction model for malignant transformation of oral potentially malignant disorders. *Oral Oncology*, 123:105619. <https://doi.org/10.1016/j.oraloncology.2021.105619>
- Cai XJ, Zhang JY, Zhang AB, et al., 2022a. Emerging role of high glucose levels in cancer progression and therapy. *Chin J Dent Res*, 25(1):11-20. <https://doi.org/10.3290/j.cjdr.b2752695>
- Cai XJ, Zhang JY, Zhang HY, et al., 2022b. Overestimated risk of transformation in oral lichen planus. *Oral Oncology*, 133:106025. <https://doi.org/10.1016/j.oraloncology.2022.106025>
- Calenic B, Greabu M, Caruntu C, et al., 2015. Oral keratinocyte stem/progenitor cells: specific markers, molecular signaling pathways and potential uses. *Periodontology* 2000, 69(1):68-82. <https://doi.org/10.1111/prd.12097>
- Cao W, Younis RH, Li J, et al., 2011. EZH2 promotes malignant phenotypes and is a predictor of oral cancer development in patients with oral leukoplakia. *Cancer Prev Res (Phila)*, 4(11):1816-1824. <https://doi.org/10.1158/1940-6207.CAPR-11-0130>
- Celentano A, Glurich I, Borgnakke WS, et al., 2021. World Workshop on Oral Medicine VII: prognostic biomarkers in oral leukoplakia and proliferative verrucous leukoplakia—a systematic review of retrospective studies. *Oral Dis*, 27(4):848-880. <https://doi.org/10.1111/odi.13363>
- Cervigne NK, Reis PP, Machado J, et al., 2009. Identification of a microRNA signature associated with progression of leukoplakia to oral carcinoma. *Hum Mol Genet*, 18(24):4818-4829. <https://doi.org/10.1093/hmg/ddp446>
- Chang YA, Weng SL, Yang SF, et al., 2018. A three-microRNA signature as a potential biomarker for the early detection of oral cancer. *Int J Mol Sci*, 19(3):758. <https://doi.org/10.3390/ijms19030758>
- Chaturvedi AK, Udaltsova N, Engels EA, et al., 2020. Oral leukoplakia and risk of progression to oral cancer: a population-based cohort study. *J Natl Cancer Inst*, 112(10):1047-1054. <https://doi.org/10.1093/jnci/djz238>
- Chaves ALF, Silva AG, Maia FM, et al., 2019. Reduced CD8⁺ T cells infiltration can be associated to a malignant transformation in potentially malignant oral epithelial lesions. *Clin Oral Invest*, 23(4):1913-1919. <https://doi.org/10.1007/s00784-018-2622-8>
- Chaves FN, Bezerra TMM, Moraes DC, et al., 2020. Loss of heterozygosity and immunoeexpression of *PTEN* in oral epithelial dysplasia and squamous cell carcinoma. *Exp Mol Pathol*, 112:104341. <https://doi.org/10.1016/j.yexmp.2019.104341>
- Chen YK, Huang AHC, Cheng PH, et al., 2013. Overexpression of Smad proteins, especially Smad7, in oral epithelial dysplasias. *Clin Oral Invest*, 17(3):921-932. <https://doi.org/10.1007/s00784-012-0756-7>
- Cruz I, Napier SS, van der Waal I, et al., 2002. Suprabasal p53 immunoeexpression is strongly associated with high grade dysplasia and risk for malignant transformation in potentially malignant oral lesions from Northern Ireland. *J Clin Pathol*, 55(2):98-104.
- de Carvalho Fraga CA, Farias LC, de Oliveira MVM, et al., 2014. Increased VEGFR2 and MMP9 protein levels are associated with epithelial dysplasia grading. *Pathol Res Pract*, 210(12):959-964. <https://doi.org/10.1016/j.prp.2014.06.020>
- de Freitas Silva BS, Yamamoto-Silva FP, Pontes HAR, et al.,

2014. E-cadherin downregulation and Twist overexpression since early stages of oral carcinogenesis. *J Oral Pathol Med*, 43(2):125-131.
<https://doi.org/10.1111/jop.12096>
- de Vicente JC, Rodrigo JP, Rodriguez-Santamarta T, et al., 2013. Podoplanin expression in oral leukoplakia: tumorigenic role. *Oral Oncol*, 49(6):598-603.
<https://doi.org/10.1016/j.oraloncology.2013.02.008>
- de Vicente JC, Donate-Pérez del Molino P, Rodrigo JP, et al., 2019. SOX2 expression is an independent predictor of oral cancer progression. *J Clin Med*, 8(10):1744.
<https://doi.org/10.3390/jcm8101744>
- Drews RM, Hernando B, Tarabichi M, et al., 2022. A pan-cancer compendium of chromosomal instability. *Nature*, 606(7916):976-983.
<https://doi.org/10.1038/s41586-022-04789-9>
- Emilion G, Langdon J, Speight P, et al., 1996. Frequent gene deletions in potentially malignant oral lesions. *Br J Cancer*, 73(6):809-813.
<https://doi.org/10.1038/bjc.1996.142>
- Fernández-Valle Á, Rodrigo JP, García-Pedrero JM, et al., 2016. Expression of the voltage-gated potassium channel Kv3.4 in oral leukoplakias and oral squamous cell carcinomas. *Histopathology*, 69(1):91-98.
<https://doi.org/10.1111/his.12917>
- Ferrer-Sánchez A, Bagan J, Vila-Francés J, et al., 2022. Prediction of the risk of cancer and the grade of dysplasia in leukoplakia lesions using deep learning. *Oral Oncol*, 132: 105967.
<https://doi.org/10.1016/j.oraloncology.2022.105967>
- Fonseca-Silva T, Diniz MG, de Sousa SF, et al., 2016. Association between histopathological features of dysplasia in oral leukoplakia and loss of heterozygosity. *Histopathology*, 68(3):456-460.
<https://doi.org/10.1111/his.12746>
- Ghosh A, Das C, Ghose S, et al., 2022. Integrative analysis of genomic and transcriptomic data of normal, tumour, and co-occurring leukoplakia tissue triads drawn from patients with gingivobuccal oral cancer identifies signatures of tumour initiation and progression. *J Pathol*, 257(5): 593-606.
<https://doi.org/10.1002/path.5900>
- Gires O, Mack B, Rauch J, et al., 2006. CK8 correlates with malignancy in leukoplakia and carcinomas of the head and neck. *Biochem Biophys Res Commun*, 343(1):252-259.
<https://doi.org/10.1016/j.bbrc.2006.02.139>
- Gomes CC, Fonseca-Silva T, Galvão CF, et al., 2015. Inter- and intra-lesional molecular heterogeneity of oral leukoplakia. *Oral Oncol*, 51(2):178-181.
<https://doi.org/10.1016/j.oraloncology.2014.11.003>
- Graveland AP, Bremmer JF, de Maaker M, et al., 2013. Molecular screening of oral precancer. *Oral Oncol*, 49(12): 1129-1135.
<https://doi.org/10.1016/j.oraloncology.2013.09.005>
- Grochau KJ, Safi AF, Drebber U, et al., 2019. Podoplanin expression in oral leukoplakia—a prospective study. *J Craniomaxillofac Surg*, 47(3):505-509.
<https://doi.org/10.1016/j.jcms.2018.12.005>
- Jäwert F, Fehr A, Öhman J, et al., 2022. Recurrent copy number alterations involving *EGFR*, *CDKN2A*, and *CCND1* in oral premalignant lesions. *J Oral Pathol Med*, 51(6): 546-552.
<https://doi.org/10.1111/jop.13303>
- Jiang WW, Fujii H, Shirai T, et al., 2001. Accumulative increase of loss of heterozygosity from leukoplakia to foci of early cancerization in leukoplakia of the oral cavity. *Cancer*, 92(9):2349-2356.
[https://doi.org/10.1002/1097-0142\(20011101\)92:9<2349::aid-cnrcr1582>3.0.co;2-i](https://doi.org/10.1002/1097-0142(20011101)92:9<2349::aid-cnrcr1582>3.0.co;2-i)
- Kaur J, Matta A, Kak I, et al., 2014. S100A7 overexpression is a predictive marker for high risk of malignant transformation in oral dysplasia. *Int J Cancer*, 134(6):1379-1388.
<https://doi.org/10.1002/ijc.28473>
- Kawaguchi H, El-Naggar AK, Papadimitrakopoulou V, et al., 2008. Podoplanin: a novel marker for oral cancer risk in patients with oral premalignancy. *J Clin Oncol*, 26(3): 354-360.
<https://doi.org/10.1200/JCO.2007.13.4072>
- Klein IP, Meurer L, Danilevicz CK, et al., 2020. BMI-1 expression increases in oral leukoplakias and correlates with cell proliferation. *J Appl Oral Sci*, 28:e20190532.
<https://doi.org/10.1590/1678-7757-2019-0532>
- Kovesi G, Szende B, 2006. Prognostic value of cyclin D1, p27, and p63 in oral leukoplakia. *J Oral Pathol Med*, 35(5): 274-277.
<https://doi.org/10.1111/j.1600-0714.2006.00396.x>
- Kreppel M, Kreppel B, Drebber U, et al., 2012. Podoplanin expression in oral leukoplakia: prognostic value and clinicopathological implications. *Oral Dis*, 18(7):692-699.
<https://doi.org/10.1111/j.1601-0825.2012.01927.x>
- Kujan O, Agag M, Smaga M, et al., 2022. PD-1/PD-L1, Treg-related proteins, and tumour-infiltrating lymphocytes are associated with the development of oral squamous cell carcinoma. *Pathology*, 54(4):409-416.
<https://doi.org/10.1016/j.pathol.2021.09.013>
- Kurokawa H, Matsumoto S, Murata T, et al., 2003. Immunohistochemical study of syndecan-1 down-regulation and the expression of p53 protein or Ki-67 antigen in oral leukoplakia with or without epithelial dysplasia. *J Oral Pathol Med*, 32(9):513-521.
<https://doi.org/10.1034/j.1600-0714.2003.00117.x>
- Kyrodimou M, Andreadis D, Drougou A, et al., 2014. Desmoglein-3/ γ -catenin and E-cadherin/ β -catenin differential expression in oral leukoplakia and squamous cell carcinoma. *Clin Oral Invest*, 18(1):199-210.
<https://doi.org/10.1007/s00784-013-0937-z>
- Lameira AG, Pontes FSC, Guimarães DM, et al., 2014. MCM3 could be a better marker than Ki-67 for evaluation of dysplastic oral lesions: an immunohistochemical study. *J Oral Pathol Med*, 43(6):427-434.
<https://doi.org/10.1111/jop.12153>
- Li XT, Liu L, Zhang JY, et al., 2021. Improvement in the risk assessment of oral leukoplakia through morphology-related copy number analysis. *Sci China Life Sci*, 64(9): 1379-1391.
<https://doi.org/10.1007/s11427-021-1965-x>

- Lin CY, Chen WH, Liao CT, et al., 2010. Positive association of glucose-regulated protein 78 during oral cancer progression and the prognostic value in oral precancerous lesions. *Head Neck*, 32(8):1028-1039. <https://doi.org/10.1002/hed.21287>
- Lin L, Wang JY, Liu DJ, et al., 2016. Interleukin-37 expression and its potential role in oral leukoplakia and oral squamous cell carcinoma. *Sci Rep*, 6:26757. <https://doi.org/10.1038/srep26757>
- Liu W, Feng JQ, Shen XM, et al., 2012. Two stem cell markers, ATP-binding cassette, G2 subfamily (ABCG2) and BMI-1, predict the transformation of oral leukoplakia to cancer: a long-term follow-up study. *Cancer*, 118(6):1693-1700. <https://doi.org/10.1002/cncr.26483>
- Liu W, Wu L, Shen XM, et al., 2013. Expression patterns of cancer stem cell markers ALDH1 and CD133 correlate with a high risk of malignant transformation of oral leukoplakia. *Int J Cancer*, 132(4):868-874. <https://doi.org/10.1002/ijc.27720>
- Maimaiti A, Abudoukeremu K, Tie L, et al., 2015. MicroRNA expression profiling and functional annotation analysis of their targets associated with the malignant transformation of oral leukoplakia. *Gene*, 558(2):271-277. <https://doi.org/10.1016/j.gene.2015.01.004>
- Mao L, Lee JS, Fan YH, et al., 1996. Frequent microsatellite alterations at chromosomes 9p21 and 3p14 in oral pre-malignant lesions and their value in cancer risk assessment. *Nat Med*, 2(6):682-685. <https://doi.org/10.1038/nm0696-682>
- Mello FW, Miguel AFP, Dutra KL, et al., 2018. Prevalence of oral potentially malignant disorders: a systematic review and meta-analysis. *J Oral Pathol Med*, 47(7):633-640. <https://doi.org/10.1111/jop.12726>
- Mello FW, Melo G, Guerra ENS, et al., 2020. Oral potentially malignant disorders: a scoping review of prognostic biomarkers. *Crit Rev Oncol Hematol*, 153:102986. <https://doi.org/10.1016/j.critrevonc.2020.102986>
- Miyahara LAN, Pontes FSC, Burbano RMR, et al., 2018. *PTEN* allelic loss is an important mechanism in the late stage of development of oral leucoplakia into oral squamous cell carcinoma. *Histopathology*, 72(2):330-338. <https://doi.org/10.1111/his.13381>
- Monteiro L, Mello FW, Warnakulasuriya S, 2021. Tissue biomarkers for predicting the risk of oral cancer in patients diagnosed with oral leukoplakia: a systematic review. *Oral Dis*, 27(8):1977-1992. <https://doi.org/10.1111/odi.13747>
- Monteiro L, do Amaral B, Delgado L, et al., 2022. Podo-planin expression independently and jointly with oral epithelial dysplasia grade acts as a potential biomarker of malignant transformation in oral leukoplakia. *Biomolecules*, 12(5):606. <https://doi.org/10.3390/biom12050606>
- Muller S, Tilakaratne WM, 2022. Update from the 5th edition of the World Health Organization Classification of Head and Neck Tumors: tumours of the oral cavity and mobile tongue. *Head Neck Pathol*, 16(1):54-62. <https://doi.org/10.1007/s12105-021-01402-9>
- Nguyen CTK, Okamura T, Morita KI, et al., 2017. LAMC2 is a predictive marker for the malignant progression of leukoplakia. *J Oral Pathol Med*, 46(3):223-231. <https://doi.org/10.1111/jop.12485>
- Odell E, Kujan O, Warnakulasuriya S, et al., 2021. Oral epithelial dysplasia: recognition, grading and clinical significance. *Oral Dis*, 27(8):1947-1976. <https://doi.org/10.1111/odi.13993>
- Pal J, Rajput Y, Shrivastava S, et al., 2022. A standalone approach to utilize telomere length measurement as a surveillance tool in oral leukoplakia. *Mol Oncol*, 16(8):1650-1660. <https://doi.org/10.1002/1878-0261.13133>
- Papale F, Santonocito S, Polizzi A, et al., 2022. The new era of salivaomics in dentistry: frontiers and facts in the early diagnosis and prevention of oral diseases and cancer. *Metabolites*, 12(7):638. <https://doi.org/10.3390/metabo12070638>
- Partridge M, Emilion G, Pateromichelakis S, et al., 1998. Allelic imbalance at chromosomal loci implicated in the pathogenesis of oral precancer, cumulative loss and its relationship with progression to cancer. *Oral Oncol*, 34(2):77-83. [https://doi.org/10.1016/s1368-8375\(97\)00052-3](https://doi.org/10.1016/s1368-8375(97)00052-3)
- Peng JK, Dan HX, Xu H, et al., 2022. Agreement evaluation of the severity of oral epithelial dysplasia in oral leukoplakia. *Chin J Stomatol*, 57(9):921-926 (in Chinese). <https://doi.org/10.3760/cma.j.cn112144-20211206-00537>
- Peng X, Cheng L, You Y, et al., 2022. Oral microbiota in human systematic diseases. *Int J Oral Sci*, 14:14. <https://doi.org/10.1038/s41368-022-00163-7>
- Philipone E, Yoon AJ, Wang S, et al., 2016. MicroRNAs-208b-3p, 204-5p, 129-2-3p and 3065-5p as predictive markers of oral leukoplakia that progress to cancer. *Am J Cancer Res*, 6(7):1537-1546.
- Pietrobon G, Tagliabue M, Stringa LM, et al., 2021. Leukoplakia in the oral cavity and oral microbiota: a comprehensive review. *Cancers (Basel)*, 13(17):4439. <https://doi.org/10.3390/cancers13174439>
- Poomsawat S, Buajeeb W, Khovidhunkit SO, et al., 2010. Alteration in the expression of cdk4 and cdk6 proteins in oral cancer and premalignant lesions. *J Oral Pathol Med*, 39(10):793-799. <https://doi.org/10.1111/j.1600-0714.2010.00909.x>
- Pritzker KPH, Darling MR, Hwang JTK, et al., 2021. Oral potentially malignant disorders (OPMD): what is the clinical utility of dysplasia grade? *Expert Rev Mol Diagn*, 21(3):289-298. <https://doi.org/10.1080/14737159.2021.1898949>
- Ramos-García P, González-Moles MÁ, Ayen A, et al., 2019. Predictive value of *CCND1*/cyclin D1 alterations in the malignant transformation of potentially malignant head and neck disorders: systematic review and meta-analysis. *Head Neck*, 41(9):3395-3407. <https://doi.org/10.1002/hed.25834>
- Ramos-García P, González-Moles MÁ, Warnakulasuriya S, 2022. Significance of p53 overexpression in the prediction of the malignant transformation risk of oral potentially malignant disorders: a systematic review and meta-analysis. *Oral Oncol*, 126:105734.

- <https://doi.org/10.1016/j.oraloncology.2022.105734>
- Ray JG, Chatterjee R, Chaudhuri K, 2019. Oral submucous fibrosis: a global challenge. Rising incidence, risk factors, management, and research priorities. *Periodontology* 2000, 80(1):200-212.
<https://doi.org/10.1111/prd.12277>
- Ries J, Agaimy A, Vairaktaris E, et al., 2012. Evaluation of MAGE-A expression and grade of dysplasia for predicting malignant progression of oral leukoplakia. *Int J Oncol*, 41(3):1085-1093.
<https://doi.org/10.3892/ijo.2012.1532>
- Saintigny P, El-Naggar AK, Papadimitrakopoulou V, et al., 2009. ΔNp63 overexpression, alone and in combination with other biomarkers, predicts the development of oral cancer in patients with leukoplakia. *Clin Cancer Res*, 15(19):6284-6291.
<https://doi.org/10.1158/1078-0432.CCR-09-0498>
- Sakata J, Yoshida R, Matsuoka Y, et al., 2017. Predictive value of the combination of SMAD4 expression and lymphocyte infiltration in malignant transformation of oral leukoplakia. *Cancer Med*, 6(4):730-738.
<https://doi.org/10.1002/cam4.1005>
- Sathasivam HP, Nayar D, Sloan P, et al., 2021. Dysplasia and DNA ploidy to prognosticate clinical outcome in oral potentially malignant disorders. *J Oral Pathol Med*, 50(2): 200-209.
<https://doi.org/10.1111/jop.13121>
- Schaaij-Visser TBM, Bremmer JF, Braakhuis BJM, et al., 2010. Evaluation of cornulin, keratin 4, keratin 13 expression and grade of dysplasia for predicting malignant progression of oral leukoplakia. *Oral Oncol*, 46(2):123-127.
<https://doi.org/10.1016/j.oraloncology.2009.11.012>
- Schwarz S, Bier J, Driemel O, et al., 2008. Losses of 3p14 and 9p21 as shown by fluorescence in situ hybridization are early events in tumorigenesis of oral squamous cell carcinoma and already occur in simple keratosis. *Cytometry A*, 73(4):305-311.
<https://doi.org/10.1002/cyto.a.20504>
- Shao S, Tsoi LC, Sarkar MK, et al., 2019. IFN-γ enhances cell-mediated cytotoxicity against keratinocytes via JAK2/STAT1 in lichen planus. *Sci Transl Med*, 11(511):eaav7561.
<https://doi.org/10.1126/scitranslmed.aav7561>
- Simple M, Suresh A, Das D, et al., 2015. Cancer stem cells and field cancerization of oral squamous cell carcinoma. *Oral Oncol*, 51(7):643-651.
<https://doi.org/10.1016/j.oraloncology.2015.04.006>
- Thiem DGE, Schneider S, Venkatraman NT, et al., 2017. Semiquantifiable angiogenesis parameters in association with the malignant transformation of oral leukoplakia. *J Oral Pathol Med*, 46(9):710-716.
<https://doi.org/10.1111/jop.12544>
- Tobias MAS, Nogueira BP, Santana MCS, et al., 2022. Artificial intelligence for oral cancer diagnosis: what are the possibilities? *Oral Oncol*, 134:106117.
<https://doi.org/10.1016/j.oraloncology.2022.106117>
- Tu HF, Lin LH, Chang KW, et al., 2022. Exploiting salivary miR-375 as a clinical biomarker of oral potentially malignant disorder. *J Dent Sci*, 17(2):659-665.
<https://doi.org/10.1016/j.jds.2021.09.020>
- van den Bossche V, Zaryouh H, Vara-Messler M, et al., 2022. Microenvironment-driven intratumoral heterogeneity in head and neck cancers: clinical challenges and opportunities for precision medicine. *Drug Resist Updat*, 60:100806.
<https://doi.org/10.1016/j.drup.2022.100806>
- Vered M, Allon I, Dayan D, 2009. *Maspin*, p53, p63, and Ki-67 in epithelial lesions of the tongue: from hyperplasia through dysplasia to carcinoma. *J Oral Pathol Med*, 38(3):314-320.
<https://doi.org/10.1111/j.1600-0714.2008.00698.x>
- Villa A, Celentano A, Glurich I, et al., 2019. World Workshop on Oral Medicine VII: prognostic biomarkers in oral leukoplakia: a systematic review of longitudinal studies. *Oral Dis*, 25(S1):64-78.
<https://doi.org/10.1111/odi.13087>
- von Zeidler SV, de Souza Botelho T, Mendonça EF, et al., 2014. E-cadherin as a potential biomarker of malignant transformation in oral leukoplakia: a retrospective cohort study. *BMC Cancer*, 14:972.
<https://doi.org/10.1186/1471-2407-14-972>
- Warnakulasuriya S, 2000. Lack of molecular markers to predict malignant potential of oral precancer. *J Pathol*, 190(4): 407-409.
[https://doi.org/10.1002/\(SICI\)1096-9896\(200003\)190:4<407::AID-PATH546>3.0.CO;2-D](https://doi.org/10.1002/(SICI)1096-9896(200003)190:4<407::AID-PATH546>3.0.CO;2-D)
- Warnakulasuriya S, Johnson NW, van der Waal I, 2007. Nomenclature and classification of potentially malignant disorders of the oral mucosa. *J Oral Pathol Med*, 36(10): 575-580.
<https://doi.org/10.1111/j.1600-0714.2007.00582.x>
- Warnakulasuriya S, Kujan O, Aguirre-Urizar JM, et al., 2021. Oral potentially malignant disorders: a consensus report from an international seminar on nomenclature and classification, convened by the WHO Collaborating Centre for Oral Cancer. *Oral Dis*, 27(8):1862-1880.
<https://doi.org/10.1111/odi.13704>
- Weber M, Wehrhan F, Baran C, et al., 2020. Malignant transformation of oral leukoplakia is associated with macrophage polarization. *J Transl Med*, 18:11.
<https://doi.org/10.1186/s12967-019-02191-0>
- William WN, Zhao X, Bianchi JJ, et al., 2021. Immune evasion in HPV⁻ head and neck precancer-cancer transition is driven by an aneuploid switch involving chromosome 9p loss. *Proc Natl Acad Sci USA*, 118(19):e2022655118.
<https://doi.org/10.1073/pnas.2022655118>
- Wood MW, Medina JE, Thompson GC, et al., 1994. Accumulation of the p53 tumor-suppressor gene product in oral leukoplakia. *Otolaryngol Head Neck Surg*, 111(6):758-763.
<https://doi.org/10.1177/019459989411100610>
- Wu XB, Wang RY, Jiao JT, et al., 2018. Transglutaminase 3 contributes to malignant transformation of oral leukoplakia to cancer. *Int J Biochem Cell Biol*, 104:34-42.
<https://doi.org/10.1016/j.biocel.2018.08.016>
- Xu SB, Wang MY, Shi XZ, et al., 2022. Influence of PD-1/PD-L1 on immune microenvironment in oral leukoplakia and oral squamous cell carcinoma. *Oral Dis*, online.
<https://doi.org/10.1111/odi.14332>

- Yagyuu T, Funayama N, Imada M, et al., 2021. Effect of smoking status and programmed death-ligand 1 expression on the microenvironment and malignant transformation of oral leukoplakia: a retrospective cohort study. *PLoS ONE*, 16(4):e0250359.
<https://doi.org/10.1371/journal.pone.0250359>
- Yang SY, Li SH, Liu JL, et al., 2022. Histopathology-based diagnosis of oral squamous cell carcinoma using deep learning. *J Dent Res*, 101(11):1321-1327.
<https://doi.org/10.1177/00220345221089858>
- Yang Y, Li YX, Yang X, et al., 2013. Progress risk assessment of oral premalignant lesions with saliva miRNA analysis. *BMC Cancer*, 13:129.
<https://doi.org/10.1186/1471-2407-13-129>
- Zhang L, Rosin MP, 2001. Loss of heterozygosity: a potential tool in management of oral premalignant lesions? *J Oral Pathol Med*, 30(9):513-520.
<https://doi.org/10.1034/j.1600-0714.2001.300901.x>
- Zhang XL, Han S, Han HY, et al., 2013. Risk prediction for malignant conversion of oral epithelial dysplasia by hypoxia related protein expression. *Pathology*, 45(5):478-483.
<https://doi.org/10.1097/PAT.0b013e3283632624>
- Zhang XL, Kim KY, Zheng ZL, et al., 2017a. Nomogram for risk prediction of malignant transformation in oral leukoplakia patients using combined biomarkers. *Oral Oncol*, 72:132-139.
<https://doi.org/10.1016/j.oraloncology.2017.07.015>
- Zhang XL, Kim KY, Zheng ZL, et al., 2017b. Snail and Axin2 expression predict the malignant transformation of oral leukoplakia. *Oral Oncol*, 73:48-55.
<https://doi.org/10.1016/j.oraloncology.2017.08.004>